

VI. *The Morphology of the Ungulate Placenta, particularly the Development of that Organ in the Sheep, and Notes upon the Placenta of the Elephant and Hyrax.*

By RICHARD ASSHETON, M.A., *Lecturer on Biology in the Medical School of Guy's Hospital, University of London.*

Communicated by ADAM SEDGWICK., F.R.S.

Received April 18,—Read June 8, 1905.

[PLATES 9-13.]

TABLE OF CONTENTS.

	Page
Introduction	144
A. THE DEVELOPMENT OF THE SHEEP'S PLACENTA—	
The State of the Uterus before Pregnancy	145
The Early Stages of Pregnancy, 1st-16th days	148
The Period of Attachment, 17th-30th days	152-163
The 19th day of Pregnancy	154
The 20th day of Pregnancy	157
The 25th day of Pregnancy	160
The 28th day of Pregnancy	162
The 31st day of Pregnancy	163
The 35th day of Pregnancy	164
The 44th day of Pregnancy	165
The 52nd day of Pregnancy	166
The 60th day of Pregnancy	169
The 78th day of Pregnancy	169
The Full Term Placenta	171
The After-birth	176
Summary of the Sheep's Placenta	177
B. THE PLACENTA OF SOME OTHER UNGULATES AND SUB-UNGULATES—	
The Pig	180
Hyrax	183
The Elephant	191
The Cow	195
C. GENERAL CONCLUSIONS	196
D. EPITOME	206
Appendix	207
Literature	208
Description of Plates	215
(244.)	9.1.06.



Introduction.

THE following account of the development of the placenta in certain members of the Ungulata Vera and Sub-Ungulata forms part of the direct outcome of a grant of money received some years ago from the Government through the Royal Society. This grant has defrayed a considerable portion of the expense incurred. During the years which have passed since I received it, I have published accounts of the development of the sheep and pig, in the 'Quarterly Journal of Microscopical Science,' and 'Journal of Anatomy and Physiology,' which work, though not the direct object for which I received the grant, was nevertheless a result of it.

I wish, therefore, to express my sincere gratitude to the Committee of the Royal Society and to the Government for having placed the money at my disposal.

My thanks are also due to my brother, Mr. NICHOLAS R. ASSHETON, and to Mr. STOTT, farmer, of Brownlow Twiston, in the county of Lancaster, for help in procuring the necessary material. To Dr. HARMER, F.R.S., Superintendent of the Museum of Comparative Anatomy at Cambridge, I am indebted for some embryos and uterus of *Procavia* (*Hyrax*) *capensis* which had been obtained and presented to the Museum by Major BARRETT HAMILTON. For the Proboscidean material I must thank Mr. F. E. BEDDARD, F.R.S., Prosector of the Zoological Society, Professor STEWART, F.R.S., of the Royal College of Surgeons and also Dr. T. G. STEVENS, of Guy's Hospital, with the last mentioned of whom I have already published some investigations on the elephant's placenta.

To Miss MARIE KRULL I desire also to express my sincere gratitude for assistance given me in my laboratory in the preparation of sections and in other ways, and most especially to my wife, FRANCES A. E. ASSHETON, for her invaluable help in the literature of this subject.

It is unnecessary for the moment to do more than draw attention to the large amount of work which has been done on the mammalian placenta, and the great advance made in our knowledge of this most remarkable organ during the last twenty years. Anyone acquainted with the work of VON BAER, BISCHOFF, COSTE, ERCOLANI, TURNER, ROLLESTON and OWEN, will know that the placenta is a subject which has not been neglected, and he will also know that it is a subject which, from a morphologist's point of view, is of great difficulty. Not only have the facts been disputed and, indeed, still are in dispute, but, granted agreement as to facts, the interpretations that can be placed thereon frequently differ.

The greater part of the work on this subject in recent years has been done upon mammals having the so-called deciduate type of placenta. Such work is that of STRAHL upon the Dog and Ferret, FLEISCHMANN on the Cat and Dog, DUVAL on the Cat, Dog, Rat, Guinea-pig, VAN BENEDEN and FROMMEL and NOLF on the Bat, JENKINSON on the Mouse, HUBRECHT on the Hedge-hog, Shrew, Mole, Tupaia,

Tarsius, etc., LANGHANS, MINOT, SELENKA, PETERS, on the Primates. The non-deciduate type has received far less attention.

In the following contribution I have tried to make good one deficiency and relate as completely as I can the process of the development of the placenta in the sheep. In addition I have given facts concerning the placenta of other ungulates and of the sub-ungulates, which tend, I hope, to clear up some of the difficulties.

A.—THE DEVELOPMENT OF THE SHEEP'S PLACENTA.

The State of the Uterus before Pregnancy.

The uterus of the sheep, as is well known, is bicornuate as regards the upper portions, but the two horns are fused along their lower parts and so form a short single tube which opens by a single opening into the vagina. Each horn tapers off gradually into the Fallopian tube.

On opening the uterus one notices the many prominences, often deeply pigmented, which, arranged somewhat irregularly, project into the cavity of the uterus. They vary in size, the larger ones occupying the middle, and the smaller the higher and lower portions.

These are the cotyledonary burrs which are present from an early period, and are quite independent of conception or rut, and it is at these points, and determined apparently by these burrs, that the attachment of the foetus to the uterus takes place. They are analogous, and, generally speaking, homologous to those areas to which the name trophospongia has been given by HUBRECHT and found by him in *Erinaceus*, *Tupaia*, *Tarsius*, etc.

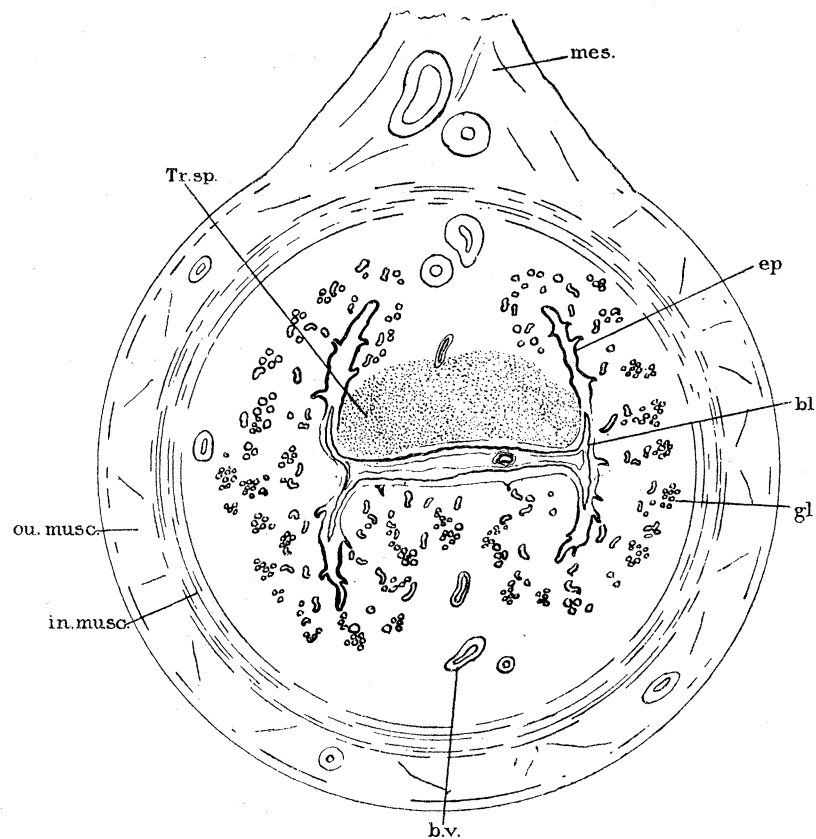
These protuberances lie against one another when the uterus is intact and not pregnant, so that the lumen is an irregular slit with the walls closely approximated (see text-fig. 1, p. 146).

The whole inner surface of the uterus is lined by a well-marked epithelium of columnar cells. According to KOLSTER (61) this epithelium is ciliated in the young animal. All trace of ciliation, however, disappears at the time of pregnancy. This epithelium dips down at intervals into the sub-epithelial tissues and forms long glands which are much branched towards their bases (*gl.*). Beneath the epithelium comes a layer of connective tissue densely crowded with nuclei, which generally are elongated and lie parallel to the epithelial surface. There are also numerous leucocytes which stain deeply and are scattered throughout this tissue and also amongst the epithelial cells.

Beneath this comes a looser tissue made up of the same kind of cells, which, however, cross one another at various angles instead of lying parallel to the epithelial surface. The whole is penetrated by capillaries which are more numerous towards the surface, while the larger vessels lie in the deeper and looser tissue of the sub-mucosa.

Beneath or outside this are the muscular layers covered externally by peritoneum. Of these I need say nothing as they are less directly concerned with the changes induced by pregnancy than the mucous membrane and sub-mucosa. For further description of the walls of the non-pregnant uterus the reader may refer to MARSHALL (65) and KAZZANDER (54).

The epithelium dips into the sub-mucosa to form glands over the whole surface, except where it covers the cotyledonary burrs. These are never penetrated by glands,



Text-fig. 1.—bl., blastocyst; b.v., blood vessel; gl., uterine gland; ep., uterine epithelium; in.musc., internal muscle layer; ou.musc., outer muscle layer; mes., mesometrium; Tr.sp., Trophospongia.

although branches from the adjoining glands may stretch beneath them, between them and the muscle layers. These glands may be of a somewhat complicated character. They are compound and tubular. The course taken by a gland is as follows: It dips down at right angles to the surface, then usually turns and runs parallel to the surface for a short distance and turns again downwards and passes by a very convoluted path into the deepest parts of the sub-mucosa, where it branches and ends in numerous tubular alveoli. Just above the point at which the several branches join the main duct a short neck leads into a short pocket, which may be dilated as a sac or bladder.

The character of the epithelium differs according to the position it occupies: whether on the internal surface of the uterus, or in the tubular part of the glands, or in the dilated sac.

The epithelium lining the cavity of the uterus is distinctly columnar, but the cells are narrow and tall, and rather taller over the cotyledonary burrs than elsewhere. The outer portions of the cells are more granular than the inner portions. The nuclei are larger and usually oval and more often than not are nearer the base than the outer surface.

Leucocytes are occasionally found lying between the bases of the cells. Certain long opaque rod-like cells or bodies are also sometimes visible and are probably effete cells. There is no particular change in the character of the epithelium as it turns down into the gland, except that the long rod-like cells are more numerous and the outer portions of the cells are clearer. Leucocytes are fairly numerous in the deeper parts. In the dilated part of the gland—the vesicle—the epithelium is shorter and less compressed, and the nuclei spherical rather than oval. The several parts of the gland are always to be distinguished in any section of the uterus of the sheep.

MARSHALL (65) has recently described the histological changes which occur in the sub-mucosa (stroma) of the uterus of the sheep during the post-œstrous cycle up to the time of pregnancy.

The changes noticed during proœstrum, œstrus and metœstrum are marked, but not so great as in many animals. They consist in an increase of the uterine stroma, a dilation of the capillaries, and usually—but not always—in a breaking down of the walls of the capillaries which leads to the extravasation of blood into the more superficial layers of the stroma and often into the cavity of the uterus, in which case small lesions occur in the epithelium.

There is also a swelling of the glands with a slight flow of secretion from them. This is followed by recuperation, namely a mending of the capillaries and epithelium and general subsidence of the congested state. The blood, which has been extravasated into the stroma, gives rise to pigment—owing to the destruction of the red corpuscles. This, in MARSHALL'S opinion, is effected by the liberated leucocytes. He notes, however, that another observer, KAZZANDER, “does not admit the agency of leucocytes” in this connection.

Pigment is extremely variable in amount, due very probably, as MARSHALL supposes, to the frequency and intensity of the previous proœstrous periods and possibly to the breed of sheep. MARSHALL presumes that the pigment is got rid of, as he has never found it in the anœstrous period. I find that it disappears slowly during pregnancy by passing into the maternal blood stream.

The condition of the uterus in the earliest of my pregnant sheep should, therefore, be similar to that described by MARSHALL for the period of rest, provided that coition and impregnation have had no effect upon it.

I cannot think that MARSHALL'S description is quite correct with reference to the epithelium. He describes it as consisting of "a double layer of cubical cells," and says of the glandular epithelium that it "is frequently composed of more than two rows of cells, especially at their openings, where it may be many layers deep." This is very unusual in glandular epithelia, and is quite unlike any specimens that I have of either pregnant or non-pregnant uteri. The epithelium in my specimens is always a single layer of long columnar cells, though the nuclei of these are not always at the same level.

Nor do I agree with the following:—MARSHALL says: "These openings" (mouths of glands) "do not occur on the surface of the cotyledons so much as between them." My experience is that they never open on the surfaces of the cotyledons. Nor can I agree with him that "no clear line of demarcation can be made out between the cells of the epithelium and those of the stroma tissue." It can be seen very clearly by staining with nigrosin.

Œstrus, if I understand him aright, occurs during the period covered by the last stages of the breaking down of the blood vessels and the first stages of the building up of the new tissue. MARSHALL does not give the actual length of the several periods. Œstrus is said to last for "a short period, and sometimes for only a few hours." The whole diœstrous cycle takes about 15 days.

Impregnation takes place in the Fallopian tube, and the ova pass into the uterus within three days of the time of dehiscence. Dehiscence normally occurs during œstrus. Ova, when dehisced, pass, whether fertilised or not, into the uterus (ASSHETON, 1898).

From the above facts it is clear that the ova arrive in the uterus during the latest stages of the metœstrum or during the early part of the succeeding period of rest. The time for the next proœstrum would accordingly be between the 12th and 16th days of pregnancy. It would be interesting to note whether this is coincident with any marked changes in the uterine mucosa. However, I believe the first serious attack made upon the tissue by the blastocyst is not until the 17th–18th day after coition, that is to say, after œstrus; whereas the next proœstrous period would be due about 15 days after impregnation.

The Early Stages of Pregnancy—1st–16th Days.

No change is noticeable in sections of the uterus of a pregnant sheep on the third day after coition, at which time the ova are still within the Fallopian tube; unless it is that the leucocytes which are present in the previous stage in the stroma, and at the base of the epithelium, now appear to be advancing into the epithelium.

Up to this time the egg is in the Fallopian tube. On the fourth or fifth day it enters the uterus, still covered by its zona radiata.

The condition of the glands is very much as in the unimpregnated uterus. They contain very little secretion and no trace of *débris*, or blood.

In the three days' and six days' pregnant uterus there are small masses of brown material, which may be collections of dead red blood corpuscles, the result of the proœstrous extravasation.

The dilated sacs are lined by a more cubical epithelium, and the cells are shorter and broader, possibly the result of some increasing pressure within the lumen of the sac. Neither the leucocytes nor the rod-like cells are as numerous as in the other parts of the gland.

The cotyledonary burr is essentially a local thickening of the sub-epithelial dense tissue, which elsewhere exists as a thin layer immediately beneath the epithelium. It is traversed by numerous capillaries which, on the whole, tend to run in a direction at right angles to the surface.

One difference to be noticed in the epithelium lining the uterus is that the leucocytes, already referred to on the previous page, can now be found scattered throughout the whole breadth of the epithelium. This occurs as early as the third day after fertilisation while the ova are still within the Fallopian tube.

In a specimen which was taken from a ewe which had been served six days previously, in which I found two unfertilised eggs but no embryo, the leucocytes are seen only at the base of the epithelium and in small quantities.

In many specimens at this age and until after many weeks of pregnancy, very irregularly shaped cells loaded with dark brown pigment are to be found in the stroma. These lie close beneath the epithelium. A nucleus is present in the bulky part of the cell and does not contain pigment. Fine granules of pigment are found also in the epithelial cells chiefly round the nuclei.

Treated with the ferrocyanide test the pigment does not show the iron reaction. This layer of pigment cells is more pronounced on the cotyledonary burrs, but is not confined thereto.

There are distinctly two kinds of pigment. One kind which, as I have described here, is variable in its occurrence, and often entirely absent (*e.g.*, it was absent in ewes, 66–69, which were old small Scotch Highland ewes, while in most of the others crossbreeds, Suffolks, and Leicesters, it was generally abundant). This when present is always close to the epithelium, and is unaffected by any stain I have used or by the Prussian blue test for iron.

The other kind lies much deeper and is more scattered and occurs in little isolated nodules generally surrounded by leucocytes. This pigment is very much lighter in colour, and stains slightly with orange G, but nothing else except thionin, with which it stains more intensely than any other tissue. It is unaffected by the Prussian blue test.

Among the epithelial cells lining the cavity of the uterus are cells containing bundles of rod-like bodies. These seem to be accompanied by leucocytes, and I think they are formed within the leucocytes. They are similar to the rod-like bodies found slightly later in the trophoblast cells of the embryo (BONNET, 12).

The development of the embryo of the sheep from fertilisation to the 10th or 11th day has been described by me in two former papers (2) (4), and from that time onwards by BONNET (12) (13). I need not refer much to these changes, except in so far as they concern the layers which come in actual contact with the walls of the uterus.

The segmenting ovum, still protected by its zona radiata, travels slowly down the uterus until the ninth day. On the ninth day the zona ruptures and the blastocyst for the first time lies in direct contact with the epithelium of the uterus. By about the 12th day it probably has reached nearly to the lower limit of the horn in which it lies, as after this time a very rapid growth takes place, resulting in the elongation of the blastocyst, which lengthens in such a way that its central portion containing the embryonic disc is close to the lower end of the horn in which it lies, while the two ends of the blastocyst grow out, one to the tip of the horn in which the blastocyst has been, and the other, if there should be but a single blastocyst in the uterus, to the tip of the other horn.

The wall of the blastocyst from the time the expansion begins on the 10th day until the 16th day is of two layers, the trophoblast and hypoblast, each of one cell in thickness (fig. 1, Plate 9).

Growth of the walls is very rapid, so that in spite of the great elongation the blastocyst undergoes, the cells, especially of the trophoblast, change from the flat stretched condition of the 10th day to the cubical shape they have assumed by the 14th day.

The 14th and 15th days show little change. I think none in length; the blastocyst now extends from end to end of the uterus. To a certain degree the length of the blastocyst must be considered to be determined by the size of the uterus and number of the embryos which never overlap. Thus, if there is one only, it will extend through both horns of the uterus, the embryo occupying the common part of the uterus; if there are two, they are each confined to one horn of the uterus and may coalesce in the undivided portion of the uterus.

The changes in the actual embryo during these days are fully described in BONNET'S papers, so I need say but little more.

The whole blastocyst becomes distinctly thicker. The greater part is didermic except in the region of the embryonal area, where the mesoblast is well formed and split into splanchnic and somatic layers. The coelom forms a cavity below the gut which is suspended therein, though it is not possible to speak of a mesentery, as the split in the mesoderm passes only half-way round the gut.

The character of the trophoblast beyond the embryonal area is similar throughout. It is a single layer of large polygonal cells with closely fitting bases, but with the outer surface convex, wedge-shaped, and often separated from their neighbours for quite half their height (fig. 1).

The hypoblast lines the blastocyst cavity as far as the extremities, and consists of

an exceedingly thin but always recognisable layer with nuclei separated by considerable intervals. These nuclei are flattened in some cases, large and spherical in others.

I have no evidence of the presence of any spot which is not lined by the hypoblast as may possibly be the case opposite the embryonal area as the result of the method of formation of the hypoblast layer (*cf.* ASSHETON (2)).

In a general view of a section of portions of the uterus at this stage, a noteworthy change is observable, caused by a great expansion of the sac-like swellings of the glands; these swellings in some cases measure as much as 1 millim. in diameter.

A closer examination reveals also slight histological changes. The leucocytes seem to have receded again, and are seldom found beyond the base of the epithelium. They are present, however, in large numbers in the sub-epithelial tissues, and also in the epithelium of the glands, and possibly may escape into the lumen, a course which, according to KOLSTER, is adopted later. The epithelium of the gland is still quite healthy and shows no change from the previous stages.

The next specimen I shall describe is a uterus from which I took two elongated embryos (text-fig. 2) which according to the date given me should have been 27 days old. Judging, however, from other embryos they were clearly much younger than this, and were probably somewhere between 16 and 19 days old.

The glands show no great change. A general increase in size and complexity of the gland goes on for some weeks, but the character of the epithelium does not change.

The cotyledonary burrs are probably increasing in size. This is difficult to determine owing to their great normal variation. The most marked change is the tendency for the tissues to arrange themselves round the larger blood vessels at the base, and the disappearance of that stratified arrangement described above for the earlier stages of the tissue immediately beneath the epithelium. This seems to be the beginning of a general loosening of the material forming the outermost part of the burr which is so conspicuous a feature later, and which is probably due to the infiltration of fluid between the more solid parts of the tissues along this region. Mitotic figures are found here occasionally. The dark brown pigment cells have been separated from each other during the process and send long straggling processes into the deeper parts of the burr. I think, also, that there is a considerable amount of pigment either alongside or inside the capillaries.

The epithelium over the inter-cotyledonary area shows but little advance upon the previous stage, but over the cotyledonary burr a much more marked advance has been made. There are distinct evidences of degeneration.

Period of Attachment, 17th-30th Days.

At some time between the 17th to the 18th day the first attachment between embryo and uterus is effected (at least this is the time at which the first attack upon the uterine tissues occurs), and results in the destruction of the uterine epithelium. This is of course a very important stage; for hitherto it has generally been held that in the deciduate placental mammals the uterine epithelium does not disappear. FRAENKEL (34) has, however, stated the contrary opinion, but he does not support it by any descriptive evidence or by figures. His note is a very short one, and he has taken for a disappearing epithelium what is really the plasmodiblast layer of foetal origin. His observations were made on a late stage of development.

It has been, however, a matter of very great difficulty to arrive at a true conclusion; for the disappearance of the epithelium is accompanied by a laying on of a layer of cells of foetal origin, so that at no time is the uterine stroma bare except over quite small areas.

I feel I must give the evidence on which I base this statement as fully and fairly as I am able to do.

That the uterine epithelium degenerates and ceases to exist in a form in any way comparable to that which it had before pregnancy no doubt can arise.

The difficulty comes in when we have to decide upon the origin of a layer of cells which, although occupying a position similar to the degenerated epithelium, resembles it in no other respect.

Does this layer take its origin from some of the cells of the degenerated epithelium, or is it a layer derived from the foetal trophoblast possibly comparable to and homologous to the plasmodi-trophoblast layer of the embryo of other mammals such as bat, dog, rat, rabbit, etc.?

The answer which I would give is that this layer does arise from foetal tissues, and that the uterine epithelium wholly disappears, at first from the surface of the cotyledons, then over a considerable area of the surface lining the uterus with the exception of the mouths of the glands. Later on in pregnancy the epithelium is formed again over that part of the uterus lying between the cotyledons and even on the sides of the cotyledons. This regeneration is effected about the ninth or tenth week.

In the uterus of the sheep on the 17th day of pregnancy no great change from the condition of a week or ten days before is visible in the muscular coats or in the sub-mucous layer, unless it is in the greater complexity of the glands. The epithelium of the glands is as before. There is no trace in the specimen I have of the 17th day of any sac-like dilations or diverticula of the glands: they are ordinary compound tubular glands.

The trophospongia of the cotyledon is more crowded with nuclei, which show a marked tendency to arrange themselves round the blood capillaries of the deeper portion; so that in section this part has the appearance of being made up of many systems of cells recalling the arrangement of cells in the Haversian systems of bone.

Moreover the dense layer of cells, which are arranged parallel to the surface, and which lie only a little way beneath the surface, is no longer recognisable as a dense layer, though the parallel arrangement is still visible in parts. It is this region which now continues to swell, partly by the increase in size and number of blood capillaries and perhaps by the increase in number of lymphatics.

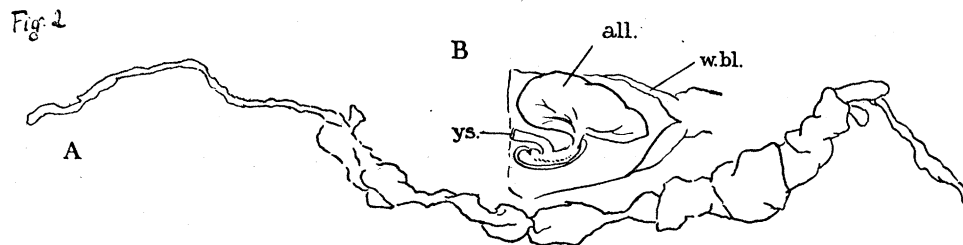
Text-fig. 1 is a slightly diagrammatic drawing of a section taken through the whole uterus containing an embryo. It will be noticed that there is only a narrow lumen, the opposing walls being almost in contact, and within this narrow and irregular lumen lies the blastocyst (*bl.*).

In the figure it will be seen that the embryo does not fill the whole lumen as yet.

The chief interest lies, however, in the epithelium of the uterus. In between the cotyledons the epithelium is still present and not materially altered from the earlier stages (text-fig. 1).

If we follow the epithelium from the deep recesses where it is intact, and to which probably the blastocyst does not extend, towards the centre of the lumen of the uterus, we find a fairly sudden change in the character of epithelium, and this change corresponds everywhere with the presence of the blastocyst, allowing for a slight amount of shrinkage in the blastocyst.

I have also specimens of the 19th and 20th days which are well preserved and more suitably fixed than the specimen from which I have drawn the above text-figure. These three specimens are of so important a stage that I must give the details of the methods adopted in preservation. The former (ovis 28, age doubtful) from



Text-fig. 2.—(Ovis 28.) Age, 16–19 days? A. Whole blastocyst removed from uterus. B. Embryonic part of blastocyst opened, showing embryo with allantois just beginning. $\times 2$.
all., allantois; w.bl., wall of the blastocyst; ys., stalks of the yolk sac.

which the specimen was taken for the drawing above, was preserved in chromic acid. One horn of the uterus was opened and the embryo separated from the uterus under picro-sulphuric acid. This is the one shown in text-fig. 2. The irregular shape it has is due to the irregular character of the lumen it occupies. The other horn was preserved whole in chromic acid and transverse sections were made of the whole uterus.

The second specimen (ovis 67, 19 days) was treated, within a quarter of an hour of the death of the ewe, by the injection into the uterus of bichromate of potash, corrosive sublimate and acetic acid solution according to ZENKER'S formula. This

separated the blastocyst from the walls of the uterus, and, no doubt, in certain places removed the now degenerated epithelium from the uterus, but it ensured perfect preservation to the sound parts.

The third specimen, that of the 20th day, was manipulated rather differently. The uterus and blastocyst, within a few minutes of the death of the ewe, were opened very carefully under ZENKER'S fluid, so that the fluid fixed the wall of the blastocyst to the wall of the uterus, thereby preserving the proper relations between the two, although as yet the attachment is of the most delicate nature.

The 19th day of Pregnancy.

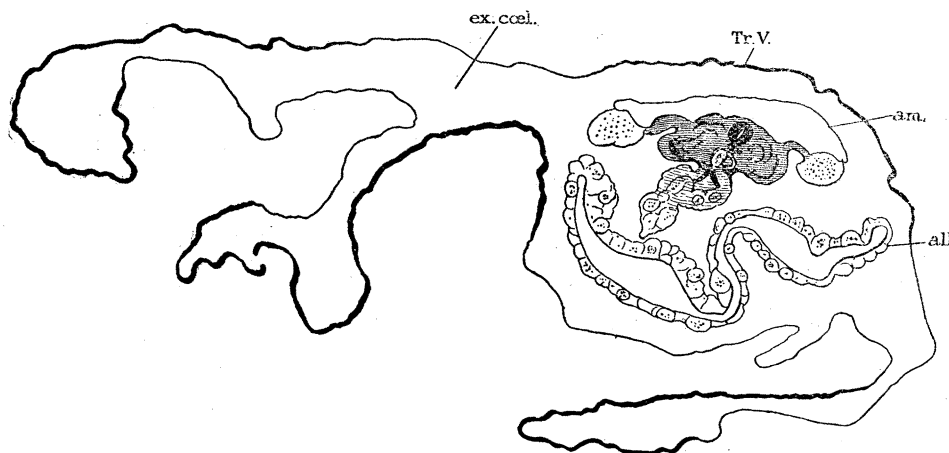
Ovis 67.

Dimensions. Length of blastocyst 360 millims.
Length of embryo 7·5 millims.

The blastocyst has attained a large size and nearly fills the cavity of the uterus, the actual size being dependent upon the number of ova which have been fertilised and are accordingly in process of development.

The trophoblast is now lined throughout by the somatopleur, which is a single layer of much attenuated cells with small darkly staining nuclei. The coelom is large and the yolk sac is pushed to one side.

The trophoblast, which on the 15th day is a single layer of cubical cells and shows no differentiation of the cells, or of thickness, becomes much thicker during the interval between the 15th and 18th days. This increase in thickness, however, is due chiefly to the change from a cubical to a more columnar type of cell, and concerns only those areas which correspond roughly but not exactly with those areas which are in contact with the cotyledonary burrs. There is, however, in the trophoblast over the cotyledonary burrs a slight heaping up of the cells. Many cells certainly penetrate the whole thickness (fig. 3), but at places there is probably



Text-fig. 3.—(Ovis 67.) Age, 19 days. Transverse section through the blastocyst in the region of the embryo. The trophoblast shows thickening over the areas which will come into contact with the cotyledonary burrs. The allantois walls show many blood vessels.

all., allantois ; am., amnion ; ex.ccel., extra-embryonic coelom ; Tr.V., thickened trophoblast.

a doubling of the layer. Moreover certain darkly staining cells with darkly staining nuclei are to be found among the others (figs. 3 and 25, *Tr. D.*), about which I shall have a good deal to say later.

Again, a further differentiation is seen in that very many of the cells contain long rod-like bodies noticed long ago by BONNET and described by him as albumen crystals.

Text-fig. 3 is a transverse section through the whole embryo and blastocyst and shows the thickened areas of the trophoblast where it lies against the cotyledonary burrs of the walls of the uterus.

It is over these areas that the thickening of the trophoblast occurs. Elsewhere the trophoblast is a single layer of cells with but slight indication of boundary walls. It may be noticed that the cotyledonary area at this period considerably exceeds the intercotyledonary area in extent.

The allantois with its extremely vascular walls is already some 15 millims. in length, one horn pointing up, the other down the lumen of the uterus. The allantois at no point touches the wall of the blastocyst. The wall of the blastocyst is quite destitute of blood vessels.

A close examination of the blastocyst as a whole at this stage shows that the thickened areas which are revealed by the section, text-fig. 3, are marked by many ridges and furrows which tend to run transversely to the longitudinal axis of the blastocyst.

Similarly the cotyledonary burrs on the uterine walls show very faint groovings, into which the ridges of the trophoblast fit. The attachment at this stage is so slight that great difficulty is experienced in keeping the blastocyst *in situ* during preparation. The next stage, however, shows conclusively the true relation between the blastocyst or uterine wall.

A section taken parallel to the long axis cuts the ridges and furrows at right angles. This is the case with the series of sections of one of which text-fig. 4 is a



Text-fig. 4.—(Ovis 67.) Age 19 days. Transverse section through the embryonic thickening. The trophoblast shows folds. Mes.so., somatopleur mesoblast; Tr., trophoblast.

drawing. This is a section through one of the thickened ridged areas of a blastocyst, and I wish to draw especial attention to the fact that the ridges are more of the nature of folds than of local thickenings. To some small extent this may be due to crumpling as a result of the method of application of the preserving fluid.

A section, however, of the uterine cotyledonary burr (text-fig. 5) shows the sulci just as plainly as the ridges appear upon the blastocyst wall.

The trophoblast cells are nearly all crowded with proteid material—the rod-like

crystals. These are far more abundant over the cotyledonary areas than elsewhere. Among the cells are a few which differ much from their neighbours. These are much denser, stain more deeply with all dyes, and have either a single nucleus, or in many cases a double nucleus which can be distinguished from the nuclei of the ordinary cells by having a more intense staining reaction and by a difference in the character of the chromatin (fig. 3, Plate 9, and fig. 25, Plate 10).



Text-fig. 5.—(Ovis 67.) Age 19 days. A section taken transversely across the centre of a cotyledonary burr of the uterus. The epithelium is seen to be indented and in places quite broken (†) \times 97.

Ep., epithelium of uterus; Str., stroma.

In the ordinary cells the chromatin is distributed partly round the periphery, with always one or two masses near the centre, leaving a large part clear. In the dark cells which are eventually usually binucleate and occasionally multinucleate, the chromatin is far more abundant and evenly distributed.

To turn now to the histology of the uterus. There is nothing to note specially with regard to the muscular layer or to the stroma. Noteworthy changes, however, have begun in the epithelium, which is quite intact over by far the greater part of the area of the uterus, and is tall and columnar, and contains a few leucocytes.

In the middle of the cotyledonary burr a destruction of the epithelium has just begun, and this destruction spreads centrifugally. This is a most critical period, for upon the correct identification of the origin of certain cells and layers at this moment depends the explanation of the future stages, and the comparisons drawn between this and other mammals as regards placenta formation.

I will give at first the account of the course of events which I believe to be correct, and will then refer to the several alternatives which have suggested themselves, and give my reasons for rejecting them.

The course of events I conclude to be as follows:—

The blastocyst wall on the 17th–18th day, consisting now of somatopleur and trophoblast only, lies closely apposed to the wall of the uterus, and is kept up against it by means of the pressure of the rapidly accumulating fluid contained in the blastocyst cavity.

Hitherto it has been drawing its nourishment entirely from the juices poured out into the uterine cavity by the uterine glands and the general lining epithelium of the main cavity of the uterus. This fluid, as KOLSTER and BONNET have shown, contains fat, proteid, *débris* of cells, leucocytes, and blood corpuscles.

It is a little curious why the thinner parts of the wall of the blastocyst should occur where presumably there is the greater amount of nourishment, while over the burrs which contain no glands the trophoblast is thick.

Probably this is due to the general thinning out of the intercotyledonary regions

(rather than to the thickening of the cotyledonary areas) in response to the stretching induced by the increase of fluid within. In the neighbourhood of the glands the connection between the wall of the blastocyst and the uterus will be less intimate, as the secretion of the glands will lubricate the blastocyst wall, and so by preventing its adherence allow it to be more easily stretched.

The destruction of the epithelium is brought on at first by the agency of the darkly staining binucleate cells of the trophoblast. These can be first recognised deep down in the trophoblast, whence they migrate to the surface (fig. 3 (*Tr. D.*) and fig. 25, Plate 11), where they are in contact with the uterine epithelium. They then insinuate themselves between the cells of the uterine epithelium (figs. 5, 7, 8, 9, Plate 9) and pass down to the base of the layer and force themselves between the epithelium and the sublying stroma (figs. 10, 11, 12). While passing down in this way they swell up and their nuclei also swell, and lying close against the stroma, give rise to a layer of cells whose fate seems to be to enter into very close protoplasmic relation with the cells of the stroma. To this layer thus formed on the 18th or 19th day, similar cells are added throughout the whole period of pregnancy. The uterine epithelium is entirely lost over the cotyledonary burrs, and over a large part of the intercotyledonary areas, though here at a later stage it is regenerated.

There is no degeneration of the uterine gland epithelium, though it changes somewhat in character, except in the extreme upper regions of the horns of the uterus, where not only the glandular tissue but also the stroma undergoes remarkable hypertrophy (*vide* p. 175) and subsequent destruction (fig. 26, Plate 10).

The 20th day of Pregnancy.

Ovis 66. 20 days.

Dimensions. Length, embryo 10 millims.

Length, allantois 25 millims.

Another 24 hours results in a considerable progress in the destruction of the uterine epithelium. The attachment between blastocyst and uterus is still slight, but sufficiently close to allow the two surfaces to retain their relative positions and here and there to remain in contact during preservation.

A superficial view (fig. 14, Plate 9) of the cotyledonary burr shows a more marked furrowing, and the ridges on the blastocyst are correspondingly more evident (fig. 2). The ridges and furrows over these areas recall the stage of ridges and furrows in the case of the pig (TURNER (103), ROBINSON (82)) at a stage beyond which the placenta of that animal never gets.

Already there are distinct indications of the villi of the later stages. These are formed as buddings along the crests of the ridges, first of the trophoblast which is followed quickly by the mesoblast. They, like the primary ridges, are foldings rather than proliferations.

The epithelium over the whole surface of the cotyledonary burr is now in a state of degeneration, as it is in the intercotyledonary spaces where the thickened trophoblast overlaps it. Where, however, the thin trophoblast is in contact with it and in the deeper crevices (text-fig. 1) it is still intact.

The centre of the cotyledon as usual shows the more advanced stages. Here in places there is a complete absence of uterine epithelium. Nearer the periphery the patches of epithelium become more numerous.

The wall of the blastocyst consists of a trophoblast layer which is no thicker than the day before, but distinctly more folded, and the mesoblast, which is still a single layer of attenuated cells, lying for the most part closely applied to the trophoblast, and therefore following it in its foldings.

The characters of the trophoblast are similar to the previous stage, but show an intensification of those characters. There are very few simple cells; nearly all contain bundles of proteid crystals (fig. 36, Plate 12), and are large and swollen, many extending throughout the whole thickness.

The darkly stained cells containing, as a rule, two nuclei are far more abundant and form a most conspicuous feature (figs. 13, 36). Except for these dark cells one might speak of the trophoblast as a single layer of large columnar, oval and conical cells.

A very great difficulty occurs in the interpretation of the various appearances, such as those seen in fig. 13, Plate 9, figs. 35, 36, Plate 12. For instance, in fig. 35 my interpretation of this section is that the trophoblast has given rise to certain cells which separate from it, and, migrating through the epithelium, cut it off from further nourishment by the stroma, by lying between it and the stroma (*T.*). The nuclei of these cells have much more brightly coloured chromatin. These are aided in their destructive work by others (*Tr. D.*) which are of a more phagocytic nature, and which, attacking from the opposite side, actually engulf portions of the epithelium (fig. 13, *Ep.*). The unabsorbed uterine cells are those seen in fig. 35 with faintly staining nuclei, no doubt in a degenerative state. The same may be seen at *Ep.* in fig. 35.

In fig. 17, Plate 10, the whole of the epithelium has gone, and its place is now taken by an irregular and intermittent layer of cells (*Tr. D.*) derived as described above from the binucleate cells of the trophoblast. Some sections of the same series show a complete absence of this layer over certain areas, so that at this stage the investing coat of trophoblast is not continuous all over. A few days later it is quite continuous, while in the later stages of pregnancy it again becomes lost at certain places.

In fig. 13, Plate 9, and fig. 36, Plate 12, there is still a little epithelium remaining unabsorbed (*Ep.*) in varying stages of demolition; the cells marked (*Tr. D.*) I take to be trophoblast.

I connect the cells (*Tr. D.*) of figs. 35 and 36 with the dark, usually binucleate,

cells of the trophoblast, because they stain in the same way and because of the presence of vacuoles, which at this stage is a characteristic of these cells ((*Vac.*), figs. 7, 9, 35, and 36):

They are certain of these same cells which, by penetrating the hitherto intact epithelium and by an intensification of the vacuolations, become the first investing cells of the layer (*Tr. D.*) (figs. 17, Plate 10).

At the edges of the cotyledonary burr I find what I take to be the commencement of uterine epithelium destruction by the trophoblast (figs. 5–12, Plate 9) exactly as I have described as occurring in the centre of the cotyledon at an earlier period. The epithelium is in this way broken up into small pieces. More of the wandering cells leave the trophoblast, and the pieces of epithelium already well worn away (presumably by digestive process of the general surface of the trophoblast (fig. 13)) are surrounded by the migrating cells and totally absorbed (*Ep.*) (figs. 13, 35, and 36).

This, I believe, is the true history of the epithelium, but it is a matter of very great difficulty to determine, and I am fully aware that other interpretations may be given. For instance, are the darkly staining cells so usually binucleate really of foetal origin? I have considered the possibility of these having been derived in the first instance from the disappearing uterine epithelium. They make their appearance first at the moment when the destruction of the uterine epithelium is commencing. Certain sections suggest the possibility of their having migrated from the uterine epithelium into the trophoblast; their migrating leucocyte-like nature suggests a connection with the leucocytes which abound in the uterine epithelium up to this time. But I reject this interpretation because:

- (a) When first found in the uterine epithelium they are always on the surface (figs. 5, 7, 8, 9).
- (b) When first found in the trophoblast they occur deeply seated.
- (c) Though similar to leucocytes in their detachable nature, they are much larger than the maternal leucocytes, have dense instead of clear cytoplasm, and no intermediate stages exist. Moreover, the supply throughout pregnancy is so great that one cannot account for their origin in this way.

It should be noticed that the destruction of the uterine epithelium is clearly due to the actual contact of the blastocyst with the epithelium, as shown by text-fig. 1, which, though semi-diagrammatic, is accurate as regards the position of the contained blastocyst and the uninjured and degenerating parts of the epithelium.

The following facts may be considered established:—

- (i) The uterine epithelium over certain areas, more especially over the cotyledonary burrs, undergoes a serious amount of destruction.

- (ii) A time arrives when at certain spots there is nothing that can be recognised as an epithelium.
- (iii) Over the greater part of the area where this destruction has occurred a layer of cells takes the place of the original epithelium.
- (iv) This layer of cells is quite unlike an ordinary epithelium—it is irregular—and later becomes intimately connected by protoplasmic processes with the subjacent tissues.
- (v) This layer is subsequently added to by cells which migrate from the trophoblast.

The difficult question is the actual origin of the dark bi-nucleate cells which give rise to the layer that ultimately lines the surface of the cotyledonary burr (fig. 17, *Tr. D.*).

In addition to the two alternatives mentioned above there is a third possibility. Are the cells in question derived from stroma cells? (*cf.* HEAPE, 38).

For this I can find no evidence at all, so I shall not consider it further; and the presence of the basement membrane is evidence against it (figs. 17, 35, 36).

I think it is impossible to determine absolutely in favour of either one or the other of the first two alternatives from the course of events up to the present time. I take, however, the view that they are cells which have come out of the trophoblast and are therefore foetal, for the following reasons:—

1. This is an interpretation which is quite open to me as a result of the study of such sections as those shown in figs. 4–13. The presence of vacuoles is characteristic of these migrating cells (figs. 7, 9, 15 and 36).

2. The layer which is formed is very unlike an epithelium such as is found among the higher vertebrata. It is sharply marked off from the sub-lying tissues at first, but afterwards becomes continuous with it (fig. 38). It is clearly not an attenuation of an ordinary epithelium.

3. The destruction of the epithelium is so violent and rapid that it seems improbable that it should stop short while the active cause of the destruction is still in existence.

4. In the later stages this layer is being continually added to by the budding-off from the trophoblast of the same elements—the binucleate trophoblast cells—up to the time of birth. This last fact, which to my mind forms a very powerful argument in favour of the view I take, I shall demonstrate later on.

The 25th Day of Pregnancy.

Dimensions: Length of the embryo, 15 millims.; length of the two blastocysts,
joined together, 500 millims.

Each horn of the uterus is now completely filled by a blastocyst.

The general shape of the blastocyst is irregular, though rather less folded and crumpled than in the previous stage. The commencing villous patches are visible in the regions nearest the embryos, but less obvious towards the extremities.

The allantois has grown rapidly, and now extends throughout the whole vesicle; and the yolk sac, except in the immediate neighbourhood of the embryo, has been forced from its close relation to the trophoblast layer by the development of the "extra-embryonic" coelom and subsequent growth of the allantois into it (text-fig. 6), and has become reduced to a solid rod of cells in correspondence with the increase of the allantois. This reduced yolk sac shows no lumen, but on its outer surface a few small blood vessels occur representing the insignificant yolk sac circulation.

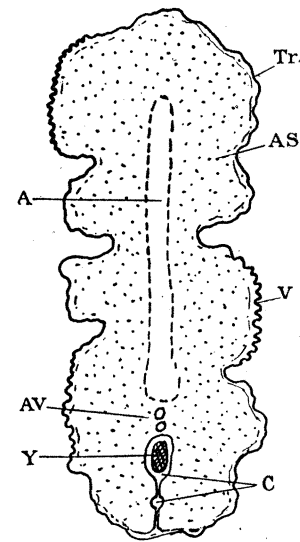
The cavity of the allantois is large. The allantoic splanchnopleur has swelled out into a thick gelatinous layer which has fused with the somatopleur underlying the trophoblast, and ventrally it envelops the yolk sac, but does not fuse with it. Thus a cavity remains surrounding the yolk sac which is the coelom. The folds of the allantois which envelop the yolk sac meet below it, but do not completely fuse. A double layer of cells forms a thin line marking this approximation extending from the somatopleur towards the yolk sac. A small canal is also left between the approximated folds of the allantois.

The character of the trophoblast has changed very considerably. It may, perhaps, still be described as consisting of one cell in thickness, but the cells are much less distinct than formerly, much narrower and taller, and the binucleate cells are now abundant and conspicuous. The blood vessels of the allantois and somatopleur lie between the somatopleur and the trophoblast, and are numerous.

In the region of the commencing villi, and marking the inter-villous areas, the trophoblast assumes an arcade-like structure, which seems to form the foundations from which the villi spring (text-fig. 7). Along these lines the trophoblast is more solid, more compact, distinctly single layered, and contains a large proportion of eosin staining cells. Each arcade projects inwards, forming a convex arch, with the basement membrane stretched tightly over it. They are absent from other parts of the blastocyst. The cells of the arcades are those characterised by the presence of the albumen rods spoken of as occurring in the earlier stage, at which time they may be found in any trophoblast cell.

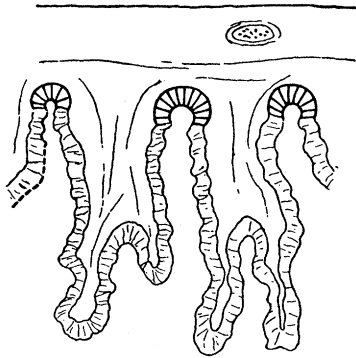
These rods are almost completely absent from the cells of the growing villi.

The degeneration of the uterine epithelium is general, and the trophospongia is more than ever packed with blood and lymph vessels. The pigment layer is more scattered.



Text-fig. 6.—Transverse section through the sheep's blastocyst of the 25th day. A, allantois; AS, splanchnopleur of allantois; AV, allantoic blood vessel; C, coelom; V, commencing folds from which villi spring; Y, solid yolk sac.

One specimen of this age (*Ovis* 37), owing to the mode of preparation, is not favourable for the purpose of the study of the fate of the epithelium, which is absent altogether from the greater part of the surface, being present only at the mouths of the glands. Certain isolated cells occur on the surface of the burr and elsewhere, which are probably of foetal origin.



Text-fig. 7. — Diagrammatic figure of the "Arcades" at the bases of the villi.

There is as yet no sign of the continuity between the cells in question and the stroma of the uterus which is established later.

In the cotyledon immediately below the scattered cells, and forming the superficial layer, comes a very loosely-built-up tissue, composed chiefly of blood capillaries, some connective tissue cells, and lymphatics (fig. 21, *T. sp.*). It is very spongy in texture, and the pigment cells, which in sections of the younger stages

lie closely packed together and near to the base of the epithelium, are now scattered and extend deep down into the cotyledon.

Beneath this is a much denser layer (fig. 21, *T. sp.*), in which the cells are closely packed and run parallel with the surface. This layer remains continuous with the corresponding layer of the intercotyledonary part. Through this layer pass the numerous and small blood capillaries, running vertically until they reach the loose spongy layer just described. Here they break off, and form a close network of fine capillaries. Many of the capillaries come close up to the surface, and consequently must lie close to, if not actually touching, the foetal cells.

About the 28th day the surface of the cotyledonary burr shows very distinctly the furrows into which the ridges on the blastocyst fit.

The nutriment received by the ovum up to the 20th day has been derived from the general lining epithelium of the uterus, and from its extension as the numerous uterine glands of the intercotyledonary areas; it is by this means alone that the blastocyst has obtained so large a size.

As it increases in size, and becomes so large as to fill the entire cavity of the uterus, and becomes more and more closely pressed against the walls, the secretion of the glands will the less readily flow, and also will be less easily brought into direct contact with the part of the blastocyst situated in the region of the burrs. At that time there is no special foetal blood supply to the future placental area.

As a consequence the cells of the blastocyst will become more and more dependent upon the nourishment they can extract direct from the cells with which they are in contact.

It is at least possible that the destruction of the epithelium may be the result of the setting up of a phagocytic action in this region, due, in the first instance, to a starving of the cells now lying closely against the burr, and deprived of the direct

nourishment they have up to the present time enjoyed from the secretion of the glands.

In a slightly older specimen there is still no firm attachment between blastocyst and uterus; they come apart at once. The villi, however, are well developed and measure 0·08 millim. or perhaps rather more, and on the surface of the cotyledonary burrs there are little depressions into which the villi fit.

The chief difference in the burr as compared with the preceding stage is the occurrence of these deeper depressions. The epithelium is almost entirely absent except around the mouth of the glands. The surface of the maternal cotyledon is more markedly furrowed and for the first time there is evidence of the commencement of the fusion of the trophoblast cells with the maternal tissues. Over the greater part of the surface of the cotyledon there is no sign of fusion.

The trophospongial tissue appears to be composed largely of vacuolated tissue. The deep cleft-like furrow suggests a process of wedge-like ingrowth on the part of the foetal tissues, combined with a swelling up around it of the soft tissues due probably to the increase of fluid in them (*cf.* fig. 22, Plate 10, of a later stage).

The destruction of the epithelium has been the result of digestive processes on the part of the foetal cells, but the further ingrowth into the burr is not a real ingrowth, but an apparent one only. There is no destruction of the stroma tissue, at any rate at the present moment, but an uprising of the stroma tissues round the elongating foetal processes, due to the oedematous condition of the maternal tissues at this point.

The 31st day of Pregnancy.

Ovis 69. Length of the embryo 17 millims.

There are no characters of the embryo to which special attention need be drawn. The great change noticeable is in the advance made by the villi upon the maternal cotyledon. The villi are now 0·5 millim. in length, branched, and covered by a layer of cubical cells, the trophoblast, which is single except for the binucleate cells, which are now very numerous on the villi. The core of mesoblast made up of loose gelatinous tissue carries the blood vessels, while the small capillaries ramify between it and the trophoblast.

The furrows are crypts and these crypts are lined by an irregular layer which, however, may be absent at certain spots. This layer is loosely attached at places, but firmly fused at others to the uterine wall.

Fig. 15, Plate 9, gives a clear idea of the character of this lining, which I believe to be the same as the irregular lining which was formed at the close of the attack upon the uterine epithelium by the foetal trophoblast (fig. 17, Plate 10). At other places, especially at the fundus of the crypts, there are larger masses of the lining which undoubtedly do fuse with the subjacent tissues (fig. 15, *Tr. pl.*, Plate 9).

In the section of this specimen there is abundant evidence of the correctness of my

view that the lining cells are foetal. The utter unlikeness of the layer in question to any kind of epithelium, and the close similarity in size, character of the nucleus and staining reaction, between the cells of the layer in question and the binucleate cells of the trophoblast are most striking.

The intercotyledonary part of the blastocyst wall is similar to the cotyledonary part, with the exception of the absence of villi. The uterine epithelium is much broken but considerable patches remain. The gland sections are numerous and in a few there are masses of cell *débris*.

The 35th day of Pregnancy.

Ovis 68. Length of the embryo 22 millims.

The layer of trophoblast cells whose nature and origin I have found difficult to determine is now present everywhere in the crypts as a very thin and irregular lining. Between the mouths of the crypts it is absent at some places.

On the intercotyledonary surfaces this layer appears to be present in places, but it is much broken by pieces of what are undoubted remnants of uterine epithelium. At the mouths of the glands, also, the uterine epithelium is present and almost normal.

I may name at once this layer of trophoblast cells, now lining the crypt, plasmoditrophoblast, for, as the sequel will show, this layer must be compared with the layer to which VAN BENEDEN gave the name in other mammals.

Fig. 16 represents a section through a crypt near the centre of one of the cotyledons.

The mesoblast forms the core of the villus and carries the branches of the allantoic arteries. The cause of the large artifact between the trophoblast of the villus and the layer lining the cavity of the crypt (between cytotrophoblast and plasmoditrophoblast) is the very gelatinous nature of the mesoblastic core of the villus which causes it to shrink during dehydration. There are certainly fewer dark binucleate cells in the trophoblast of the villus than there were in the trophoblast during the previous stage. They are, however, numerous in the intercotyledonary areas. At certain points these cells seem to have no connection with the sublying tissues, but at others, especially at the fundus of a crypt, where often two or more nuclei are lying close together, thin strands of the cytoplasm may be seen in direct continuity with thin strands of protoplasm of stroma cells. I am not satisfied that there is any actual engulfment of cells, but probably a transmission of nutriment may take place along these protoplasmic strands.

The question of the formation of the crypts is not an easy one to answer. The villi grow by their own interstitial growth; and so far there can be no question of a drawing out on their part, for they grow in thickness as well as length up to the present time. Whether they literally grow into the maternal tissues either

mechanically or by a phagocytic or other action on the part of their cells is another matter. There is no evidence beyond what I have just mentioned of any real phagocytic process. Even if there may be a slight ingrowth by this phagocytic action (which is an act of absorption rather than of engulfment) yet the whole appearance seems to suggest a growing or folding up of the tissues of the trophospongia round the advancing villi, as I described in the previous stage. I do not mean so much a growth up by multiplication of cells as a swelling up due to the great increase of vascularisation and vacuolation of the trophospongia which is now taking place (fig. 22, Plate 10).

In some places the plasmoditrophoblast cells at the bottom of the crypts appear to send their processes between the stroma cells (fig. 22), which are themselves greatly vacuolated, which cavities I think become ultimately the cavities of lymph or blood channels. The larger masses of trophoblast are often in close connection with the blood capillaries, at least in this early stage of the formation of the cotyledonary interdigitation. This is always more evident at the fundus of a crypt than elsewhere (fig. 16).

The 44th day of Pregnancy.

Ovis 11. Length of blastocyst 25 centims. Greatest diameter 5 centims. Length of the embryo 32 millims.

The foetal cotyledons are scattered roughly in lines over the whole surface of the blastocyst. They vary, however, very much in development, being only just visible near the extremities, but are attached to the uterus in the widest region.

Fig. 18, Plate 10, shows one of these villous patches on a large scale where the ridge and furrow arrangement manifests itself.

It is only in the median region that the villi do not come away quite easily—even here the attachment is not by any means firm. Here the length of the villus and corresponding depth of the crypt is 2·2 millims. Elsewhere, where the villi are well formed, but still unattached, the corresponding measurement of villus and crypt is about 1·1 millims.

Over the surface of the intercotyledonary area little rings of raised tissue occur which, although smaller, resemble the rings present in the pig's chorion. These correspond to the openings of the uterine glands.

I do not notice any histological changes of importance, except an increasing intimacy between the plasmoditrophoblast layer and the uterine tissues. Here and there this layer is still quite free from uterine tissues. On the sides of the crypts it becomes thinner and less obvious towards the entrance to the pits, and on the surface of the cotyledon I find no trace at all of it.

As regards the uterine tissues the glands are more diffuse, no doubt due to the general increase in growth and expansion of the walls of the uterus. The

cotyledonary burrs have the internal face (*i.e.*, the face next the embryo) slightly concave, and the external border of the trophospongia markedly convex. The crypts penetrate roughly perpendicular to the concave surface and so have a radiate arrangement.

Figs. 19 and 20, Plate 12, illustrate respectively the fundus of a crypt and an apex of a villus of this stage—not, however, corresponding ones.

The fact I want to draw attention to in these figures is that in the fundus there is a plasmodial layer and in it are two dark staining elongated nuclei. These I take to be those of a binucleate cell which has just passed from the foetal villus trophoblast and become adherent to the uterine wall.

On the tip of the villus (fig. 20, *Tr. D.*) an almost identical pair of nuclei occurs, forming part of the villus trophoblast, but with a very close resemblance to the two nuclei in the fundus (fig. 19). A little to the right of this there is another pair of nuclei not so dark as the above mentioned, but darker than the majority of trophoblast cells.

These three pairs of nuclei represent, I take it, the stages of translation from a close attachment to the foetal villus to a firm attachment to the walls of the crypt. Thus, at this period also, the process of formation of a plasmoditrophoblast and of its application to the walls of the uterine crypts continues.

In the more terminal cotyledons of this age the proportion of the penetrated part of the trophospongia to the non-penetrated part is 1 : 1. In the older stages, in which the attachment is firm, the proportion is nearly 2 : 1. This disproportion increases as pregnancy advances, so that at full term it is about 13 : 1. The actual thickness of the unpenetrated portion does not diminish to a great extent from this time (44 days) till just before birth, when it is only slightly less than half the present size.

This, of course, suggests that there is a mutual elongation of the cotyledonary intervillous areas and the foetal villi rather than any great amount of ingrowth by phagocytic or other action. Even the reduction in thickness by one-half or more between the 44th day and birth may be accounted for by lateral stretching, which probably takes place during the great growth in diameter which undoubtedly does occur.

The 52nd Day of Pregnancy.

A specimen of whose age I am uncertain, but which I believed to be about 52 days, contained an embryo measuring 44 millims. in length and is an advance upon the last stage described.


A great increase in the vascularity of the walls of the uterus has taken place. The glands show no difference in general arrangement or size; but the cells are less columnar and, indeed, should be described as cubical. Blood vessels are abundant about their walls. So in the cotyledon the increase in vascularity is marked.

The cotyledon is larger than any found previously, though the length of villus and depth of crypt do not show much increase. They measure about 2·3 millims.

The most easily recognised change is in the attenuation of the inter-crypt areas towards their bases, so that the more foetalwards parts are large club- or mushroom-shaped areas borne on thin stalks (text-fig. 8). Their terminal expansions are specially vascular, the capillaries being swollen and arranged in a network on the surfaces of the masses (fig. 23 (*mat. b.v.*), Plate 10).

The number of binucleate cells is very great, but I see no better marked plasmodial layer on the sides of the crypts than in the preceding stages.

In the text-fig. (8) the foetal parts have been omitted. The characters mentioned above are very obvious. With reference to the question of phagocytic action, the condition represented in the figure certainly favours the supposition of an active ingrowth of some kind on the part of the foetal villi, though probably more by an absorption than an ingestion of *solid* particles, such as one usually understands by phagocytic action. If the apparent ingrowth was in reality entirely a



Text-fig. 8.—A portion of the maternal part of the cotyledon of the sheep's placenta on the 50th day.

mutual spinning out, we should hardly expect to find a so much greater attenuation of the deeper parts than of the parts nearer the surface. If, however, the villi are constantly branching and eating their way in wherever they can get access, then a greater attenuation of the deeper parts is just what we should expect.

Fig. 37, Plate 11 shows a piece of foetal villus (*v.*) lying between two inter-crypt columns of maternal tissue (*Str.*) taken about half-way between the mouth and fundus of the crypt. This was stained with borax carmine and treated subsequently with picric acid. The foetal villus is cut so as to pass through the base of the trophoblast layer, very little mesoblast tissue is visible.

The chief points of interest to be noticed in this are the character and distribution of the binucleate cells and the plasmoditrophoblast layer lining the crypts.

In the foetal villus a number of them may be seen as doubly nucleated cells having a dense cytoplasm which is usually contracted away from the surrounding tissues, and perhaps from their own cell walls. Anyhow the appearance is that of a more or less spherical or ellipsoidal mass of protoplasm containing two nuclei. This protoplasm assumes a more pronounced orange or yellow ochre colour than any other tissues in the villus. The nuclei stain a deeper red and are also characterised by having more numerous and larger chromatin granules than any other nuclei. This character is especially easily noted by use of a pure nuclear stain such as methyl-violet or safranin after thorough washing.

Similar nuclei (*Tr. D.*) lying in similar cytoplasm lie on the maternal strands (*Str.*) and form here and there a row (which might be mistaken for a degenerate epithelium), and at other places small clusters of cells (*Tr. D.*). At one point an isolated cell with two nuclei can be seen attached to the maternal strand.

I cannot help coming to the conclusion that these two sets of cells are identical, and that their origin is foetal. On the foetal villus they are seen in process of formation, and on the maternal strands they are at their definitive destination.

In fig. 38 the fundus of one of the crypts is shown lined by the foetal cells with nuclei still healthy. It is interesting to note how the nuclei here appear in pairs, probably due to their origin as binucleate cells. If this is so then clearly the yellow mass in fig. 38 is a typical plasmodium, formed by the fusion of originally separate cells. The villus with its cytotrophoblast layer has retracted. The cause of the plasmodium remaining fixed to the fundus of the crypt is clear enough. There is an intimate connection between the plasmodium and the stroma of the trophospongia. The cytoplasm of the plasmodium is drawn out into fine strands which are woven or rather spun together with the fibrils of the stroma tissues. I can see no sharp boundary between the two, though the colours are sufficiently distinct and the one merges into the other imperceptibly.

This is a matter of considerable interest; for here are a number of originally quite separate cells, and, as I believe, of foetal origin, which fuse together, and then subsequently fine processes from the plasmodium become spun together with the fine fibrils of the stroma and form a continuous protoplasmic connection between foetus and mother. This fine protoplasmic continuity is of secondary origin.

That such a continuity exists and must be of secondary origin seems to me to be of interest in connection with the question of the origin of protoplasmic continuity in the formation of nerve fibres.

The nourishment, therefore, in this part of the placenta is obtained not by the close apposition of the foetal and maternal blood vessels, for there is a curious absence of small maternal capillaries in this region—but by protoplasmic conveyance, unless we are to presume that this arrangement just described is only a method of obtaining fixation. This alternative, however, seems to be negatived by the very rich capillary supply of foetal blood at the termination of the villi; it is more obvious still at a later stage.

It is of interest to recall the observation made by ROBINSON on the pig's placenta. ROBINSON finds in the pig (and I fully confirm this) that the trophoblast cells send out processes which penetrate between the cells of the epithelium of the uterus, which epithelium persists in that animal. These processes are comparable to those described above in an earlier stage (fig. 22, Plate 10). Whether in the pig they actually penetrate the epithelium and become continuous with the subjacent tissue is not stated. It would be interesting to determine this point.


The 60th Day of Pregnancy (or thereabouts).

The length of the embryo is 67 millims. The length of the foetal villi and depth of the uterine crypts is about 8 millims., or more than three times that of the preceding stage. This length or depth is not greatly exceeded during the subsequent weeks.

There is a further attenuation of the deeper parts of the inter-crypt column, but the upper areas next the foetus are still comparatively massive strands (text-fig. 9).

At the earliest stages the foetal villi are more in the form of ridges (fig. 18) than villi. By this time, and indeed in the previously described stage, the villi are real villi and are approximately circular in cross-section and fit into sub-circular crypts.

The text-fig. (9) shows the general form of the crypt and should be compared with the preceding text-fig. 8 on p. 167. But, except for the great deepening of the crypt that has occurred and for the greater attenuation of the inter-crypt areas, there are no changes of importance to notice. The groups of foetal cells at the fundus of the crypt are larger and the nuclei more crowded.



Text-fig. 9.—A portion of the maternal part of the cotyledon of the sheep's placenta on the 56th day. These nuclei again in this stage are in all respects similar to those of the binucleate cells of the trophoblast. They are often found in pairs, and often as binucleate cells, and are in many cases obviously only loosely attached.

The condition of the intercotyledonary region has not altered. There is no regeneration of epithelium, and the plasmodial layer is not very evident.

The 12th Week of Pregnancy (78 Days).

The general characters of the fully formed placenta are now established. The length of the foetus is 220 millims. The advance made during the past three weeks consists in—

- (a) A further attenuation of the deeper parts of the intercrypt columns of the trophospongia;

- (b) The regeneration of the uterine epithelium over the intercotyledonary area ;
- (c) The extravasation of blood to form lacunæ of maternal blood lying between the bases of the foetal villi of the *cotyledonary area* and the apices of the intercrypt columns of the trophospongia.
- (d) The formation of lacunæ of uterine milk at places between the uterine epithelium and the chorion of the intercotyledonary area.

The occurrence of the lacunæ of extravasated blood seems to me to be of great interest in consideration of the relation between the placentation of an ungulate with that of a carnivore or other of the so-called deciduate mammals.

I have not found any communication between these blood spaces and the maternal vessels ; probably there is no permanent communication. This condition in the sheep must be regarded as a very early stage in the evolution of a condition which has been attained in the type characteristic of a rodent, insectivore, or the Anthropoidea (or the last vestige of a disappearing condition ?).

In all probability the lacunæ have been derived from the bursting of such large blood spaces as occur in the apices of the intercrypt columns which are seen in fig. 23 of the 54th day of pregnancy.

It is not difficult to imagine the gradual conversion of such temporary and local bleedings into a condition in which by the persistence of the opening of rupture of the maternal vessels a permanent circulation of the maternal blood in these lacunæ could be set up during pregnancy, and so give rise to the condition, such as occurs in the elephant, and also to the somewhat different state found in the Rodents, Insectivores, and Anthropoidea.

As the uterus swells with the increasing size of the contained blastocyst, it becomes more and more apparent that the greater part of the swelling is confined to the common part of the uterus and to the lower region of the horn or horns.

This leaves the upper part of each horn but little larger than its normal size. At this stage, the 12th week, the extreme upper ends of the blastocyst extend into these small undilated parts of the uterus as much crumpled terminal sacs.

The walls of these sacs show no trace of nuclei, and must be regarded as now "structureless" membranes through which the juices contained in this part of the uterus can easily diffuse.

The mucous membrane of the uterus of this region is thrown into folds (which include portions of the glands), and are covered with a high columnar epithelium which is in a most active state of secretion. The much-folded foetal sac is thus bathed in a rich secretion of the uterine epithelium, and contains within it the same material. The glands, which stain very differently to the epithelium lining the general cavity of the uterus, are dilated, and are lined by a short cubical epithelium. The lumen contains only traces of secretion, and here and there a fragment of cellular tissue.

The preserving fluid used was Mann's micro-corrosive formalin fluid. When stained with thionin, followed by eosin and orange G, the nuclei of the glandular

epithelium stain blue; the nuclei of the epithelium of the lining of the uterus red purple, the outer borders of this same epithelium and the denser particles of the coagulation in the cavities of the uterus and foetal sac orange. Among the uterine epithelial cells are large spheres which stain deeply purple with eosin, but are untouched by thionin. In a few places the uterine epithelial cells appear to be wasting away, and even to have disappeared altogether.

This process has gone even further in later stages (*vide* p. 175).

The Placenta at Full Term.

I killed a sheep just before parturition, that is to say, the birth of the lamb was expected any day. The date, however, of impregnation was not accurately known, but the sheep would have been one of the last of a small flock of sheep to lamb. So we may conclude that it represents at any rate approximately the full-term placenta.

Very considerable changes have taken place during the three last months of pregnancy. The largest cotyledons measure from 25-30 millims. in diameter, an increase of only 5-10 millims., and the villi and crypts measure about 10 millims. The glands are much changed. They are larger; all parts show a distorted lumen and usually contain some coagulum and occasionally some cell *débris*. In many places the epithelium is thrown into folds which project into the cavities of the tubules. The epithelium is much more irregular, and shows the (i) ordinary columnar cells; (ii) high elongated cells with projecting ends; (iii) cells similar to mucous goblet cells; and (iv) leucocytes (fig. 24).

These leucocytes have spherical but not large nuclei, always one nucleus to the cell and a spherical or ellipsoidal cytoplasm, which is quite clear and has a tough cell wall. They lie at all levels in the epithelium and vary much in size. In fig. 24 one is seen to be *between* two cells upon which and their nuclei it exercises evident pressure.

Probably the three types of cell alluded to above are really different stages in the life history of one kind.

The secretion stains much more darkly in the mouths of the glands, which is perhaps due to the action of the preserving fluid. Glands now underlie a large part of the cotyledon. The sub-mucosa tissue is loose and contains a number of blood vessels.


The *epithelium* of the uterus, except in the extreme upper parts of the horns, has quite regenerated, and lines the whole of the uterine surface, including the sides of the cotyledons, but is absent from the surface and crypts of the cotyledons, and from the extreme upper ends of the horns of the uterus.

A large number of leucocytes occur—far more frequently than in the gland epithelium.

The nearer the epithelium is to the crest of the cotyledon, the less regular and shorter the cells become. They can, however, be traced as far as the edge of the first crypt in some cases. In others, the epithelium seems to terminate abruptly with

a little hillock, or more probably a ridge. I can find no trace of doubly nucleated cells in the uterine epithelium. I have no evidence as to how the epithelium is regenerated. It takes place between the 60th and 80th day.

The cotyledonary area has undergone great changes. In the maternal tissue, the inter-crypt areas have been reduced to thin laminæ by the repeated branching of the foetal villi, which are now themselves filamentous. With reference to the deeper parts of the villi it may be said that they have undergone less change than the more superficial parts. The essential characters are as they were. There are perhaps



Text-fig. 10.—A portion of the maternal part of the cotyledon of the sheep's placenta at full term.

This accumulation of blood is present in all the cotyledons from about the 75th day to birth at full term. This extravasated blood in this position is of interest on account of the resemblance which the elephant's placenta bears to it (*vide* p. 191), and, in a smaller degree, that of the dog.

fewer binucleate cells in the foetal villi. On the other hand, these cells where they line the crypts are more numerous and form large heaps of very distorted and compressed remnants including fragments of chromatin, and are everywhere abundant upon the walls of the crypts (fig. 39).

The text-fig. (10) illustrates the great attenuation undergone by the intercrypt walls. If this figure is compared with text-fig. 9 and text-fig. 8 it will be seen that in addition to the great attenuation and interdigitation that has gone on, there has been a remarkable change in the most external parts of the intercrypt walls.

These are no longer large unbroken masses, but are, nevertheless, still recognisable by their less irregular shape, dead appearance, and absence of plasmodial layer (fig. 27, Plate 11, *M.*).

The most interesting feature is the accumulation of extravasated blood which, presumably maternal, has passed into this region and lies between the foetus and the mother.

Into this blood reservoir numerous folds of the foetal epithelium (*i.e.*, trophoblast) hang, and are clearly concerned in the absorption of it.

This extravasated blood is shown in figs. 27 and 28, Plate 11.

The character of the trophoblast is quite different where it is in contact with the blood to anywhere else.

In fig. 28, Plate 11, the trophoblast (*Tr.*) appears to have its outer cell walls bulged out with fluid and laid up against the blood mass where, no doubt, a process of absorption of blood fluid is taking place into the cell interior. (Actual ingestion of the blood corpuscles occurs in places.)

At first sight it looks as though this might be an illusion, and that the appearance is due to contraction of the blood mass in the process of preservation, and that the fine strands (*x*), which I take to be the cell walls in section, are merely coagulum strands connecting the blood clot with the trophoblast cell layer. I am, however, convinced that this is not the case, but that the strands in question are without doubt the cell walls seen in section, and that the trophoblast cells here have expanded vesicular ends which are absorptive sacs.

This interpretation is rendered the more certain by the occurrence of areas where there is no blood actually in contact with the trophoblast. Here, as indicated in fig. 29, Plate 11, the sac-like terminations in the trophoblast cells are unmistakable.

The trophoblast, all along the area which forms the base from which the villi arise, shows quite a different character to that covering the villi itself. There are two kinds of cells to be distinguished here as hitherto, though the distinction is not perhaps very great. There are the columnar cells, fig. 29, Plate 11, comparable to the ordinary cells of the epithelium of the villi and the binucleate cells to be compared, no doubt, with the binucleate cells of the epithelium of the villus. I am not sure as to what the fate of the binucleate cells is in this region. I see no sign of their becoming attached to other tissues, maternal or otherwise. (They may, however, be seen in the lacunæ of maternal extravasated blood in a degenerate condition (*ref.* HUBRECHT, Tarsius?)). They are, however, active, and many mitotic figures occur along this region whereby singly nucleated cells become doubly nucleated (fig. 25, Plate 10).

The whole surface is thrown into folds, so that the base of the large villi is also the base of many smaller villi and folds. These latter dip into the blood sinuses (figs. 27, 28).

In many places these minor folds and villi lie so as to bring their respective trophoblast layers in contact with one another, fig. 28. Here a process of breaking down seems to be going on. Here and elsewhere in this region, though more especially here, the cells have become greatly swollen and contain grains of a brown pigment. There are nuclei scattered at wide intervals, most of which seem to be derived from ordinary trophoblast cells, but occasionally a binucleate cell may be seen (in fig. 28 at *Tr. D.*). These nuclei seem to be quite healthy, but I have not seen any mitotic figures actually within these broken-down areas. These are confined to the more columnar still absorbent regions.

Fig. 27 illustrates the general character of the foetal side of the placenta. Lying next to the chorionic surface is the region just described. From the chorion arise the larger villi (*V.*) which branch repeatedly, carrying the foetal blood vessels deep into the cotyledonary burr. The brown hypertrophied cells of the basal region are continued for short distances along the villi, but gradually merge into the ordinary trophoblast which retains very much the same characters as in the preceding stage. The villi, except at their bases, contain but little mesoblastic tissue beyond the blood vessels and their contents. This may be noted by a glance at fig. 39, Plate 12, in which a villus containing a large blood vessel may be seen giving off small branches at right angles to its surface, all of which is covered by an epithelium consisting almost entirely of ordinary cells of the trophoblast. The binucleate cells are far less frequent now than in the earlier stages. This figure is of part of the section close to the foetal surface.

The character of the maternal tissue is also indicated in fig. 27 (*mat. cot.*) and figs. 39, 40, Plate 12. It is broken up into a network of blood vessels carrying strands, in the meshes of which lie the foetal villi. These meshes are almost parallel in the deeper region, but more reticulate towards the foetal surface. It is much broken up and attenuated by the ingrowth of innumerable small villous branches. In fig. 39 the line lettered *Cap. m.* runs to a maternal capillary. Here there is not much stroma tissue except the blood vessels. The nuclei of the stroma tissue (*Str. n.*) are very much lighter in colour than others which lie on the surface of the maternal tissue and which are foetal in their origin, being the separated off double nucleated trophoblast cells.

In both the foetal and maternal parts there is very little connective tissue; the blood vessels of the maternal tissues are distinct vessels with endothelium, and are for the most part rather larger than capillaries. The smallest foetal vessels are small capillaries.

The blood of the foetus is thus separated from the blood of the mother by the endothelium of the foetal capillaries, the chief cells of the trophoblast, which are large and vigorous, the endothelium and walls of the maternal vessels, and in certain places by the detached cells of the trophoblast (*Tr. D.*') (plasmoditrophoblast) as well.

If the reader will follow one (more especially the one on the right) of the two main intercrypt columns of maternal tissue in fig. 27, Plate 11, towards the foetal border, he will see that its terminal portion (*M.*) differs materially from the deeper part. It has no, or at any rate very few, blood vessels; it is thicker and very compact and fibrous, and contains but few nuclei, and such as are present seem to be without vitality. These are the portions which in an earlier stage, fig. 23, are especially vascular at their edges and are not penetrated by the villi to so great an extent as the deeper parts (see text-fig. 8).

In fig. 40 of Plate 12, I have given an illustration of a portion of the distal

end of a foetal villus of this same age (full term) and of the fundus of the crypt in which it lies.

The fundus of the crypt is remarkable, as it is in all the previous stages, for the large number of foetal cells which form a distinct plasmodium, which is much more firmly attached to the maternal than to the foetal tissues.

In fig. 40 the cells of the foetal portion (*V.*) are nearly all cytotrophoblastic, with the exception of a few mesoblastic (*mes.*) cells and blood vessels (*Cap. f.*). At *Tr. D.* there is a large binucleate cell which, in its staining, both as regards its nuclei and its cytoplasm, resembles closely the cells of the plasmodium lining the fundus. It is on the point, as I take it, of becoming detached from the villus and fusing with the plasmodium.

Thus we see that at the tips of the villi the process of proliferation of the plasmoditrophoblast continues up to the end of pregnancy, having begun on the 18th day. It ceases earlier, however, on the sides of the villi, fig. 39.

A crowded group of intensely stained nuclei occurs opposite the line *Tr. D'*, fig. 40. These very deeply staining nuclei I look upon as degenerate, and in many instances they are broken up, and fragments of chromatin lie scattered in the plasmodial cytoplasm.

The space seen in the figures between the villi and walls of the crypt is, as explained above, an artifact.

It is, of course, conceivable that the villi might hang loose, so to speak, in the crypts and be bathed by a nutritive fluid exuding from the maternal tissues. This, according to KOLSTER (59), is the case in the mare, and I believe this is the case in the intercotyledonary areas where, at places, the foetal and maternal growths are separated. In the cotyledon, however, there is no such space or fluid at any time, with the exception of the extravasated blood described above at the bases of the villi.

The needle-like crystals already mentioned, figs. 13, 36, are still present in certain places, *e.g.*, in the trophoblast ordinary cells of the chorion at the base of the villi. They stain deeply with safranin, and slightly with orange G.

KOLSTER, in his paper (59, 61) on the nourishment of the embryo of the indeciduates, describes the folding inwards of the walls of the glands of the uterus of the mare when five months pregnant. These folds involve the periglandular tissue as well as the epithelium. The epithelium "disappears," and the folded-in piece of the periglandular tissue becomes separated off and is found lying within the cavity of the gland.

I have found foldings in the walls of the glands during the more advanced stages, but I have found only very slight evidence of separation of whole cells or pieces of tissue as described by KOLSTER in that part of the uterus in which the foetus lies.

In the small length at the extreme end of each of the two horns of the uterus, there is a fluid of creamy consistency which is made up of broken down maternal

tissues—large cells, groups of cells, leucocytes and general cell detritus, of nuclear and cytoplasmic origin. A section (fig. 26) through the wall of the uterus reveals a remarkable state of degeneration. This is the region described on p. 170, in which a very active secretion was in progress.

The epithelium which lines the cavity of the uterus has completely disappeared, and the general surface of the uterus is in a state of hypertrophy and desquamation. This applies more especially to the glands, but also to the interglandular tissue.

In the deeper tissues, which are very highly vascularised, the numerous sections of glands show that in almost every case the lumen is filled with "secretion." Some of the sections of glands are not very abnormal, but others show that the epithelium has undergone hypertrophy, so that the cells are large and have enormous nuclei, and form proliferating areas, while within the cavities lie cells and cell detritus.

The nuclei in many cases appear to grow enormously and break up, setting free numerous fine chromatin granules.

As on the surface, so in the deeper layers, I am inclined to think that some of the hypertrophied cells are of interglandular tissue origin. There are large irregular spaces filled with detritus, whose walls are made up of the large proliferating cells. Some are certainly of glandular origin, and their connection with the half-destroyed segments of glands is obvious; but I think also that some of the cells may be of interglandular cell origin, especially those which do not stain deeply.

The appearance of the successive changes noticed in the character of the enormous nuclei resemble closely the changes described by DUVAL in the maternal cells of the serotina of the placenta of the guinea-pig, forming his "pulpe diffuente" with fragmentation of the nucleus (chromatilysis (TAFANI)).

The function in the case of the sheep is probably the production of pabulum.

The After-birth.

The after-birth of the sheep comes away from the ewe often as long as three hours after the birth of the lamb. It is said that a certain but very varying amount of bleeding also accompanies and follows the after-birth.

From a knowledge of the structure of the placenta before birth, we should expect bleeding to occur from the lacunæ of extravasated blood which must be tapped on separation of the after-birth from the walls of the uterus. Some of the bleeding may also be due to rupture of the foetal vessels of the chorion.

I find no evidence that maternal tissue, except the extravasated blood, is lost.

TURNER (103) concluded from his examination of the after-birth of the ewe (also cow) that certain cells "having the form and appearance of the epithelial cells lining the pits in the cotyledons" were of maternal origin. Some of these he figures, and they are clearly the binucleate cells so often alluded to above, and, which I have shown, are derived from the trophoblast.

TURNER further writes (p. 110), " So far as my observations have gone, I have only detected the epithelial element of this uterine mucosa intermingled with the foetal villi ; but from the bloody state of the external parts of the ewe for some hours after the birth of the lamb, I think it not improbable that the disruption of some of the maternal cotyledons has been deeper than a mere epithelial shedding—that the maternal vessels have, in some places at least, been torn across so as to give rise to the hæmorrhage."

From his observations he declares himself of the opinion that the placenta of ruminants is deciduate.

It is extremely difficult to prove that the maternal part of the cotyledon is never ruptured. But from my own observations upon the after-birth, I believe that the normal course of events is as follows :—

At birth the loss of foetal blood pressure and of fluid within the membranes leads to a shrinkage of the tissues of the foetal part of the placenta. Each villus consists of a core of a cellular jelly-like substance containing the foetal blood vessels, and covered by a continuous layer of trophoblast cells, usually cubical in shape, and intermingled with the binucleate cells, which are continually being budded off and applied to the walls of the crypts.

At birth the shrinkage is followed by the separation of the mesoblastic part (jelly and vessels) from the trophoblast. The former comes away intact, but the greater part of the trophoblast remains within the crypts—at least so far as the distal parts of the villi are concerned.

At the proximal ends—that is to say, at the bases of the villi—the trophoblast remains attached to the mesoblastic part of the villus, and so comes away. Therefore the term *contradeciduous* must be applied to the placenta of the sheep rather than *deciduous* or *non-deciduous*.

I have searched the after-birth carefully for traces of glycogen, but have discovered none. The trophoblast cells, more especially the large binucleate cells thereof, contain fat. There are traces of free iron in certain places, chiefly in the inter-cotyledonary chorion. The pigment of the intervillous arcades is iron free ; it responds neither to the Prussian blue nor the hæmatoxylin tests of MACALLUM.

Summary of the Development of the Sheep's Placenta.

Changes in the Uterus.—On the arrival of the embryo in the uterus the condition of the mucous membrane is that typical of an anœstrous period of the œstrous cycle. A general increase in the complexity of the glands with increased secretion, a slight thickening perhaps of the stroma, and an invasion of the epithelium by the leucocytes, which are extremely numerous in the stroma immediately beneath the epithelium, are the only features which mark the first 15–18 days of pregnancy.

Changes in the Uterine Epithelium.—The embryo is by the 18th day occupying the whole length of the uterus, so rapid and so great has been the growth of the

horns of the blastocyst. The actual embryo measures about 10 millims. A destruction of the uterine epithelium commences on the 18th day over the cotyledonary areas and extends subsequently over all parts of the uterus which are in contact with the blastocyst.

Over the cotyledonary areas it never regenerates until after parturition, but over the intercotyledonary areas a regeneration takes place about the tenth week of pregnancy.

In the extreme upper regions of the horns of the uterus a much more extensive destruction of maternal tissue occurs during the last weeks of pregnancy, involving not only the epithelium but other tissues of the mucosa. This is, however, of a different nature to the earlier loss of epithelium in the other parts, the one being of an inherent pathological character, the latter due to the direct action of the blastocyst upon the maternal tissue.

Changes in the Glands.—An increase in length and complexity occurs; the secretion at first seems to be either very watery or else is exuded with great rapidity, for the lumina of the section are nearly always clear and apparently empty of coagulum. By the 30th day leucocytes, coagulum and even occasionally what may be called *débris* are found. On the 70th day the lumina increase greatly in size, the epithelium is no longer regular, but is uneven and often thrown into folds, and many of the lumina contain large masses of cell *débris*, as described by KOLSTER. The several portions of the glands are separated from each other owing to the swelling of the intervening tissues. This condition continues till birth. A copious flow of nourishment is poured out at the mouths of the glands to be taken up by the chorion.

At the extreme upper ends of the horns of the uterus this process is exaggerated and whole tracts of the epithelium of the glands, together with the adjoining stroma, become hypertrophied and break down into a pabulum. This does not occur until quite late in pregnancy.

The Changes in the Stroma.—I doubt very much whether there is any great increase in the number of cellular elements of the stroma. There is, however, a very great increase in the gelatinous matrix of the deeper (outer) layers of the stroma and a rearrangement of the cells of the upper (inner) layers, which give rise to a great increase in the vascularisation and lymph system of those parts.

In the cotyledons the innermost layers, quite the superficial layers of the special stroma tissue (trophospongia), are chiefly concerned in this latter phenomenon and to this phenomenon is mainly due the envelopment of the foetal villi.

The blood vessels on the crests of the intervillous columns of trophospongia burst about the 10th week of pregnancy and give rise to lacunæ of extravasated maternal blood, which bathe the bases of the foetal villi.

The naked surface of the stroma after the destruction of the epithelium, described in a preceding paragraph, is covered by a layer of cells derived from the foetus which, perhaps, is the equivalent of the plasmoditrophoblast of other forms.

Changes in the Outer Walls of the Embryo (Trophoblast).—The blastocyst of the 15th day reaches from end to end of the uterus. On the 18th day it has expanded in width so much that all parts of the cotyledonary burrs are in contact with it. Up till about this time the trophoblast has been an even layer, one cell in thickness, with no differentiation of cells. Now it is distinctly thickened, the cells are columnar instead of cubical and, perhaps, they form two layers over certain areas which correspond roughly with the cotyledonary areas of the uterus.

Moreover, certain cells which are within the trophoblast, but are migratory, and have as a rule two nuclei, appear for the first time, and are especially abundant in these thicker areas. These attack the epithelium of the uterus, insinuate themselves between the cells of the epithelium and, together with the ordinary cells of the trophoblast, bring about the destruction of that layer. The thickened areas are raised into folds which run transversely and fit into corresponding grooves in the uterine burrs (trophospongia).

At certain places the crests of these folds become little buds into which the mesoblast of the somatopleur follows and later (23rd–24th day) the mesoblast of the splanchnopleur carrying the allantoic vessels. These little buds, which are “hollow buds,” not solid proliferations so far as the trophoblast is concerned, “penetrate” deeply into the trophospongiat tissues and give rise to the typical villi of the cotyledonary placenta.

Although this penetration is possibly due in part to an ingrowth by the binucleate cells already alluded to by some process of absorption—though not I think by true phagocytic action—I believe the process would be described more accurately by saying that the binucleate cells, by becoming firmly attached (actual protoplasmic continuity having been acquired) to certain small areas of the maternal stroma, the future fundus of the crypt, retard at those spots the increase of the rapidly swelling up trophospongia which is now taking place around it, and so allow of the envelopment of the villi by this expanding trophospongiat tissue.

At the base of the villi small folds of the trophoblast lie bathed in extravasated maternal blood.

The intercotyledonary part of the trophoblast has generally the same characters as the trophoblast at the bases of the villi in the cotyledonary areas, and lies for the most part close to the surface of the uterus, except at the mouths of the glands, where it is separated by an accumulation of gland secretion. Round these spots the trophoblast shows a thickened ring, comparable to that found in the pig.

At birth the greater part of the trophoblast cells of the villi are left behind in the crypts and presumably absorbed by the uterus.

The bleeding which may occur at birth is probably due to the escape of the maternal blood from these lacunæ of extravasated blood.

Physiology of the Placenta.—KOLSTER has so recently treated of this that I need not say much at the present time.

I find pigment in the cells at the bases of the villi which may be regarded as an excretory product (*cf.* elephant). Free iron can be detected in a few places in the chorion, and more rarely in the villi.

Fat occurs in the uterine milk and in the trophoblast cells.

Clearly the more important part of the nourishment of the embryo is derived from the secretion by the uterine glands and general uterine epithelium, and by the breaking down of parts thereof into pabulum which is taken up by the intercotyledonary part of the chorion. The fact of the accumulation of pigment in the bases of the villi leads one to suspect that the cotyledonary area is more concerned with excretion and possibly with respiration than with nutrition.

B.—THE PLACENTA OF SOME OTHER UNGULATES AND SUB-UNGULATES.

The Pig.

The history of the first 10 days' development was published by myself in 1898, in which account I showed that the embryo during the first 10 days retains its primary spherical form, but on the 11th day, by which time the blastocysts have become scattered along the whole length of the uterus, the process of elongation commences and proceeds with great rapidity, so that by the end of the 14th day they have grown so much as to fill completely the whole length of the uterus. They vary in length according to their position, and they never overlap each other (*v.* ASSHETON (3)).

KEIBEL (55) has described the subsequent history of the development of the embryo.

By the 15th day, owing to the numerous concertina-like foldings of the blastocyst, a considerable amount of the epithelium of the uterus must be in contact with the trophoblast of the blastodermic vesicles, though not by any means all, as the vesicle is, as yet, very narrow, perhaps 3 millims. in diameter, and the mucous membrane of the uterus is much folded.

The general characters of the placenta of the pig are well known from the works of VON BAER, ESCHRICHT, TURNER and, more recently, ROBINSON, who has added some important histological details in his Hunterian Lecture, 1903.

I have thought it well to make an examination of the state of the uterus during the early stages until the formation of such connection as exists between the foetus and uterine walls, and so I give herewith a brief abstract of the results of my examination.

The Pig on the 5th Day of Pregnancy (Sus 31).—The flabby mucous membrane of the uterus is thrown into folds in various directions, the larger ones being transverse. The epithelium is tall, columnar, and vigorous. The glands, though less numerous than in the sheep, are longer and more branched, and the branches more closely packed. The epithelium of the glands is cubical, the lumen small and contains some coagulum.

The Pig on the 8th Day (Sus 14) and 10th Day (Sus 18).—The foldings of the mucous membrane increase and involve the gelatinous sub-epithelial tissue, but not as a rule any part of the glands. The epithelium shows signs of degeneration, the nuclei are less regular and the cell boundaries less well marked.

The Pig on the 14th Day (Sus 2).—The epithelium lining the cavity of the uterus is no longer columnar, the nuclei are enlarged and a general state of degeneration has supervened. The glands are very active, their epithelium is as vigorous as ever, and the lumina contain secretion.

The Pig on the 17th (Sus 15) and 18th (Sus 16) Days.—The interglandular tissue has increased somewhat. The epithelium lining the general cavity of the uterus is reduced to a thin layer. The nuclei are irregular and show little chromatin. Compare figs. 31, 32.

The Pig on the 21st Day (Sus 7).—In a specimen which was from a sow killed on the 21st day, and so presumably only three days older than the previous one, a very great change had occurred.

The whole of the surface of the uterus was very much folded, and wrinkled by little unevennesses which are not apparent to the naked eye. The sub-epithelial tissue has swollen up enormously, due to the formation of a gelatinous tissue between the stroma cell nuclei. The epithelium, which in the last stage showed undoubted signs of degeneration, now appears to be quite intact—and built up of long columnar cells with distinct boundaries. Each has an elongated nucleus, quite different from the swollen spherical or shapeless nucleus of the 17th day specimen (fig. 33).

The inner half of the cell is granular and in this half the nucleus lies. The outer half is clear and bladder-like with convex outer end. The whole cell is quite twice the height of the epithelium in the previous stage. On to the outer ends, the convex ends of the epithelium, the trophoblast of the embryo fits closely. The trophoblast is a syncytium showing no trace of cell boundaries. It contains large spherical and oval nuclei which are larger in the concavities than convexities. Fitting closely on to the epithelium cells the syncytium appears to send processes between the outer bladder-like expansions of the epithelium cells. I can see no evidence of a deeper penetration so as to pass between the cells and reach the sub-epithelial tissues as is described by ROBINSON (82). On the contrary, I see only a row of bulging maternal cells between which bulgings the trophoblast cells fit, but do not penetrate. This occurs chiefly on the apices of the ridges of the uterine folds, where the outer bulging portions of the epithelium would naturally be somewhat parted, and is not perceptible on the hollows. The deeper penetration seen by ROBINSON is a later development.

The trophoblast cells are all alike—no doubly nucleated cells occur.

The mesoblast does not invariably dip into the folds of the trophoblast but sometimes passes across them. The blood corpuscles of the foetus are large and nucleated.

The Pig on the 25th Day (Sus 24).—A specimen of 25 days exhibits only a further

accentuation of these characters. Thus the changes which have so suddenly supervened on the condition of the 17th day are :—

- (i) A great increase in the foldings of the surface of the uterus.
- (ii) A great increase in the thickness of the tissue immediately below the surface, thereby separating the epithelial surface from the glandular tissue by a considerable space.
- (iii) A great increase in vascular tissues in this sub-epithelial tissue, especially immediately beneath the epithelium.
- (iv) The formation of the gelatinous intervening substance.
- (v) A recovery on the part of the uterine epithelium.

ROBINSON (82) has recently given some details on the development of the pig's placenta. His youngest specimen was one in which the embryo measured 8·5 millims. This must have been about 19 or 20 days, and at this time the chorion has already become as closely attached to the uterine walls as it ever will be. He has missed the earlier stages in which the epithelium almost disappears. The change is very rapid. At 17 days my embryo measures only $3\frac{1}{2}$ millims. and corresponds to fig. 7 of KEIBEL'S *Normentafeln*. The embryo of my 20-day pig to fig. 16 of the *Normentafeln*.

ROBINSON thinks it probable "that although the secretion of the glands is of considerable importance for the nutrition of the ovum in the stages which precede the intimate apposition of the trophoblast with the decidual epithelium, it becomes less important afterwards."

I should doubt this. There are circular areas on the chorion as described by various authors, which form little domes over the mouths of the glands and which, no doubt, like the corresponding structures in the sheep's placenta absorb the secretion of the glands throughout foetal life.

These little cups are scattered along the courses of the blood vessels where also the mesoderm is thickened. The trophoblast is higher, and less syncytial. The outer surfaces stain deeply with orange G as though filled with the secretion of glands which also takes this stain readily.

As compared with the sheep, the most striking similarities are :—

- (i) The tendency of the trophoblast to form folds and the uterine wall corresponding furrows, which are interglandular in position.
- (ii) The tendency of the trophoblast to remain a single layer.
- (iii) The complete envelopment of the embryo by the allantois, and persistence of its cavity throughout foetal life.
- (iv) The early diminution of the yolk sac, with its circulation and disappearance before the end of pregnancy.
- (v) The nourishment by glandular secretion and by close approximation of the blood vessels (though always separated by trophoblast—and over the

greater part by uterine epithelium as well) in each case through the agency of the trophoblast.

The differences which occur in the sheep are :—

- (i) Differentiation of the trophoblast into two kinds of cell.
- (ii) The appearance in the sheep of a migrating plasmodium-forming layer which attacks and destroys the uterine epithelium, and so allows of a still closer approximation of blood vessels of foetus and mother.
- (iii) The conversion at certain places of the ridges and furrows into papillæ (villi) and formation of corresponding crypts in the maternal tissues which form the well-known cotyledons.
- (iv) The extravasation of maternal blood to form lacunæ of blood in which certain of the villi of the foetus hang, and where the consumption of maternal blood takes place directly.

I think we may legitimately compare the local swelling up of the maternal stroma tissue which occurs only on the cotyledonary burrs with the general condition of œdema which pervades the whole mucous membrane in the pig. Possibly the layer of very dense tissue which immediately underlies the epithelium may have some effect in preventing this condition in the sheep. It is above this layer (*i.e.*, strictly inside of it) that the swelling up occurs in the sheep which produces the growth round the foetal villi.

The cotyledonary type is clearly due to the presence of the trophospongia. Is it the presence of the trophospongia, which creates areas from which all glands are absent, and reduces the supply of "milk" to the trophoblast over those areas, which causes the trophoblast in those areas to become more aggressive?

Hyrax.

The aberrant genus Hyrax is usually placed near the Ungulata vera, together with the Proboscidea. It is therefore fitting that I should add some remarks upon observations made upon specimens of *Procavia* (*Hyrax*) *Capensis*, which, through the kindness of Dr. HARMER, F.R.S., Superintendent of the Comparative Anatomy Museums of Cambridge, I have been able to examine.

The specimens alluded to were preserved in spirit, and were sent by Major BARRETT HAMILTON to Dr. HARMER for the Cambridge Museum.

The development of Hyrax has not yet been investigated. Isolated stages have been described by HUME, OWEN (77), MILNE EDWARDS (69), HUXLEY (52), GEORGE (36), and TURNER (103).

It is generally admitted to have at full term a zonary placenta, a persistent allantoic cavity, but no yolk sac.

The opinion expressed by these authors is varied. OWEN says: "there is a localised annular placenta, with decidua, as in the elephant."

According to MILNE EDWARDS it is non-deciduous and similar to that of a Ruminant.

HUXLEY says it is deciduate ; “ the maternal vessels pass through the thickness of the placenta towards its foetal surface, on which they anastomose, forming meshes through which the vessels of the foetus pass toward the uterine surface of the placenta.”

TURNER, who again examined HUXLEY'S specimen, found an interlocking of foetal and maternal tissues similar to the condition in the Carnivora (Cat). He says : “ Hyrax agrees, therefore, with Felis not only in the form and structure of the placenta, but in the large size of the sac of the allantois ; it differs in the condition of the umbilical vesicle, which disappears in Hyrax apparently at an early period, but remains in Felis to the end of utero-gestation.”

The young specimen, which I shall now describe, shows no great resemblance either to the elephant, or the Ruminants, or Carnivora.

It is clearly of what I have called the cumulate* type, and so far as one can judge from an isolated specimen, resembles more closely the type of placenta found in the Rodents, Insectivora (Erinaceus), and man.

I received three objects : One was a portion of the uterus containing an embryo intact, the second was the muscular layer of another portion of a uterus, from which had been removed the third object, which was the placenta, stripped from the muscle coats, and containing the embryo. The placental tissue must have completely surrounded the embryo, it being only opened by a longitudinal slit along the side, and a short transverse slit running at right angles from the long slit to the part which lay along the mesometrium.

There was no appreciable difference between the two uterine swellings containing the embryos. They measured 22 millims. by 16 millims. One contained an embryo which was in a much younger stage than the other, equivalent to about a five-day chick or to KEIBEL'S fig. 14 of the pig (Normentafeln) (56).

From a letter from Major BARRETT HAMILTON I gather that the embryos were not from the same mother.

The condition of the membranes is as follows :—There is no trace of the uterine cavity, which is apparently completely blocked up by the embryo and its membranes.

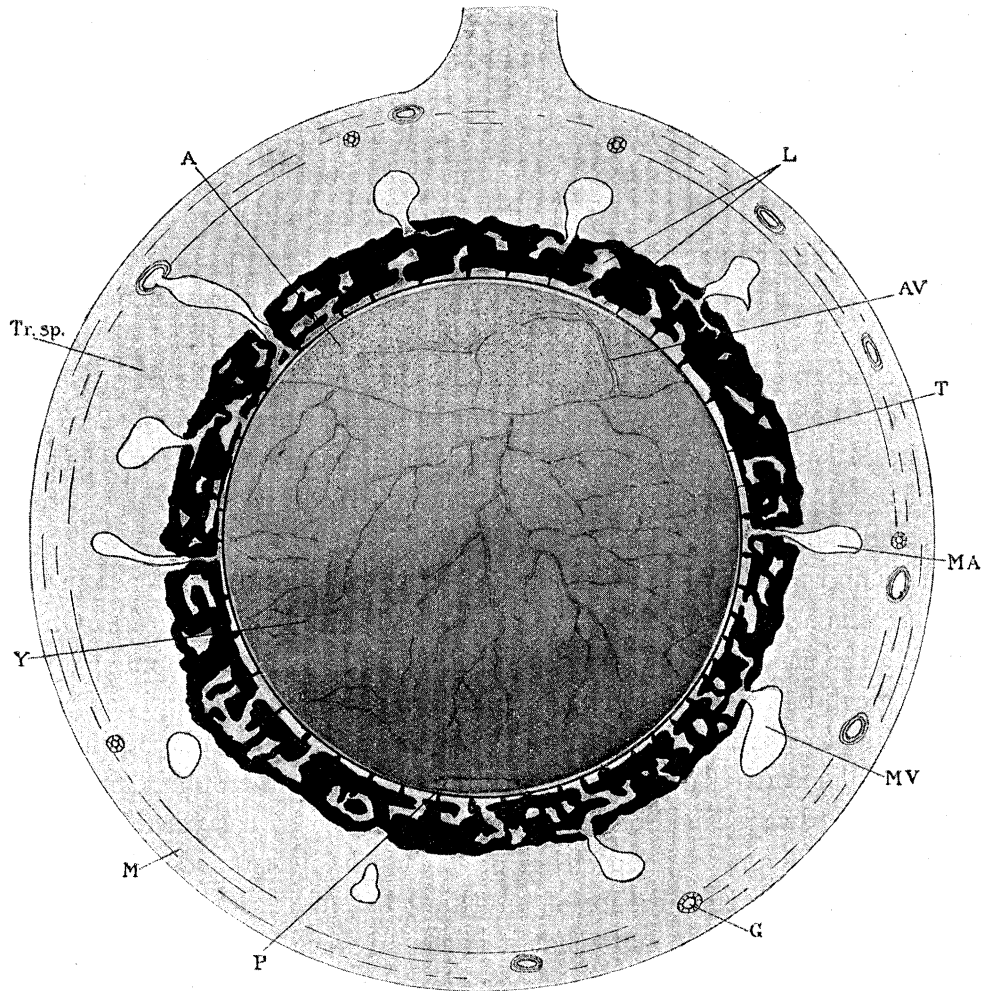
The walls of the uterus are lined throughout the swelling by a thick layer of what—so far as one can express an opinion without having followed the development—must be identified as the trophoblast. This layer of thickened trophoblast forms the outer wall of the blastocyst over its whole surface, ends as well as sides. It apparently is equally thickened throughout (text-figs. 11 and 12, and fig. 30, Plate 11, *Tr.*).

In the younger specimen (text-fig. 11) within the trophoblast, and absolutely separated from it, lies the embryo in its amnion, and that part of the embryonic membranes which are covered with splanchnopleur, all covered apparently by the somatopleur. The relations are here shown in text-fig. 11.

* *Vide* p. 199. Also abstract in the ‘Proceedings of the Royal Society,’ vol. 76.

Possibly in the living specimens this portion is closely apposed to the trophoblast. On the other hand there may be a space here filled with fluid which prevents the too close approximation of the allantois until it has completely enveloped the embryo and yolk sac. Anyhow the parts in question showed no sign of adherence.

There were two large clots of maternal blood lying between the trophoblast and somatopleur. I know nothing of their origin. Probably they were the result of some slight injury during the act of preservation.



Text-fig. 11.—*Procavia (Hyrax) Capensis*. Wall of uterus and trophoblast of embryo seen in transverse section, the rest of the blastocyst bounded by the somatopleur in surface view. The dotted area of the latter is the allantois.

A, allantois; AV, allantoic blood vessel; G, uterine gland; M, muscle layer; L, lacunæ in trophoblast filled with extravasated maternal blood; MA, maternal artery; MV, maternal vein; P, lower pole of yolk sac; T, trophoblast; Tr. sp., trophospongial layer; Y, yolk sac.

The embryo itself, which measures about 5·5 millims. from the mid-brain to the posterior flexure, was placed with its head dipping down into the yolk sac which was large and covered with a network of blood vessels.

There is no sinus terminalis, though there is a very minute area at the ventral pole in which no vessels are visible in a surface view. (Text-fig. 12, *P.*)

The upper pole of this inner sphere is formed by the allantois (*A.*), which is a hollow sac, the outer wall of which is covered by a network of large blood vessels which reach it by four main trunks, three of which are larger than the fourth.

There is no vestige as yet of any allantoic or of omphaloidean villi.

The inner wall of the trophoblast is everywhere quite smooth.

The transverse section of this wall (uterus + trophosphere) taken through the middle region, shows on the outside the muscle coats, which are very thin and much broken up by blood vessels, chiefly seen in transverse section. This forms rather less than a quarter of the whole thickness of the wall in question. Within this there is a thin layer of loose tissue, which also contains blood vessels seen in cross-section, and here and there a section of a gland (*G.*) cut transversely; but these occur very sparingly and are scattered fairly evenly all round. Inside this, and forming quite half of the whole thickness of the wall, is a layer of stroma analogous to the trophospongia, which is made up of a reticulum of cells, the general trend of whose walls and processes is concentric. On the outer border they form fine fibrils, upon which the nuclei stand out boldly, while on the extreme inner border each nucleus is the centre of a sub-spherical mass of cytoplasm. A perfect gradation pertains between these two extremes. In this region there are numerous blood vessels which run obliquely or radially, and there are no glands.

Within this and forming the inner surface of the wall and about a quarter of the whole thickness is a tissue which I take to be wholly trophoblastic (*T.*). On the outer side, bounding the stroma layer just described, there is a thick columnar epithelium.

The histological detail of the specimen is far from being perfect, and so I cannot speak with certainty as to its relation; but, I think, it shows protoplasmic continuity with the stroma cells similar to that described above for the plasmoditrophoblast of the sheep.

It is, moreover, always lined on its inner foetal surface by a layer of cells separating it from the blood sinuses. The position of the nuclei is towards the foetal surface. This fact, together with the absence of anything like a basement membrane on the maternal side leads me to conclude that it is the advance edge of the trophoblast and not the uterine epithelium. The staining reaction also suggests the same interpretation.

Within this comes a mass of trophoblastic cells honeycombed with spaces (*L.*) filled with maternal blood, which increase in size nearer the inner edge, and here may be seen to open into much wider sinuses, the innermost walls of which are quite thin. There is no sign of a somatopleur layer of mesoblast. (I did not cut the embryo.)

These blood spaces are at many points in obvious communication with the large blood vessels in the stroma of the uterine wall. These vessels in the stroma are wide intercellular spaces more than vessels, and simply open upon the surface up against which the trophoblast is firmly pressed (if not in continuity).

Opposite these openings are gaps in the columnar epithelium-like layer, which I

take to be the advance edge of the trophoblast, by which the blood obtains access to the lacunæ in the trophoblast.

These are clear and numerous. There are two kinds of openings. Some lead into channels which penetrate deeply and seem to carry the blood straight to the foetal side of the trophosphere. These have a lining of a peculiar syncytial tissue, having large nuclei which, like their cytoplasm, stain very slightly. These are confined to the middle region of the embryo swelling, and almost certainly may be said to convey the arterial stream (*M.A.*).

The other kind of opening is not lined by any such syncytial layer, and opens into channels which are apt to run parallel with the columnar epithelium. These I take to be the openings for the venous stream. Text-fig. 11 (*M.V.*).

It is, of course, impossible to speak with certainty, but the fact that the lining layer alluded to in connection with the presumably arterial channels is in direct continuity with the walls of the channels in the stroma, and nearly always shows a very sharp boundary line between itself and the trophoblast, points to its being of maternal origin, and probably an ingrowth of cells along the channels of the arterial stream.

These facts I have shown diagrammatically in text-fig. 11, page 185.

This arrangement of blood supply is very usual in placentas, by means of which the maternal arterial blood is taken at once to the foetal side of the placenta. *Cf.* Mouse (*JENKINSON*); Rabbit (*DUVAL*). That there should be apparently so slight a connection, if any, between trophoblast and somatopleur is, I believe, unusual.

So great a development of the trophoblast maternal circulation with so complete an absence of foetal villi and of foetal mesoblastic tissue in connection therewith is more akin to the condition in the Rodents (though in them the area of the greatly thickened trophoblast is restricted to a cap), and in Erinaceus and man which it resembles in being formed over the whole surface, though in them there is an early penetration of the allantois. In the human ovum (*PETERS* (78)), there is at a much earlier stage a similar vascularisation of the trophoblast, but here already the mesoblast of the foetus has penetrated, carrying within it foetal blood vessels.

I should like to emphasise the following facts: (i) the extreme tenuity of the trophoblast, where it separates the maternal blood supply from the allantois and yolk sac vessels; and (ii) the apparent absence of all protoplasmic continuity between trophoblast and somatopleur; and (iii) the fact that a layer of trophoblast and trophospongia completely surrounds the embryo, thereby entirely cutting off any secretion that might be produced by the uterine glands. All these tend to show that at this stage the whole of the nourishment received by the foetus is received direct from the blood of the mother.

There is a definite pigment (iron free) along the advancing edge of the trophoblast, and in some of the adjoining stroma cells, just as occurs in the corresponding position in the placenta of rabbit or hedgehog. I have not been able to find either glycogen or fat.

One wonders what exactly is the meaning of the lacunisation of the trophoblast. The maternal blood is carried direct to the foetal surface, where it is brought in close contact with the foetal blood vessels, after which it trickles back through a complicated system of lacunæ in the trophoblast, which is without connection with the foetus. The object of this cannot be a further direct supply of nourishment to the embryo—for there is no connection; it may be simply for the nourishment of the trophoblast itself, the direct purpose of which is probably to produce rapidly a large area of maternal blood containing channels which will easily and rapidly interdigitate with the allantoic villi as soon as they arise, or it may possibly have some special excretory action, an explanation suggested by the presence of numerous pigment granules in the outermost layers of the trophoblast, or, it may be, the secretion of some substance of use in its effect upon the mother.

On investigating the cavity of the opened specimen (which proved to be the older specimen) I found the embryo, which corresponds in stage of development to about a 16-day rabbit or 32-day sheep, lying enclosed in its amnion and attached to the walls by four bundles of blood vessels. These meet to enter the embryo at the umbilicus (fig. 30).

The allantois appears to envelop the embryo, that is to say, it completely lines the trophoblast, which has developed ectoplacental tissue over its whole surface, both sides and ends.

Possibly the whole ovum becomes embedded in the mucosa like the ovum of *Erinaceus* or *Man*.

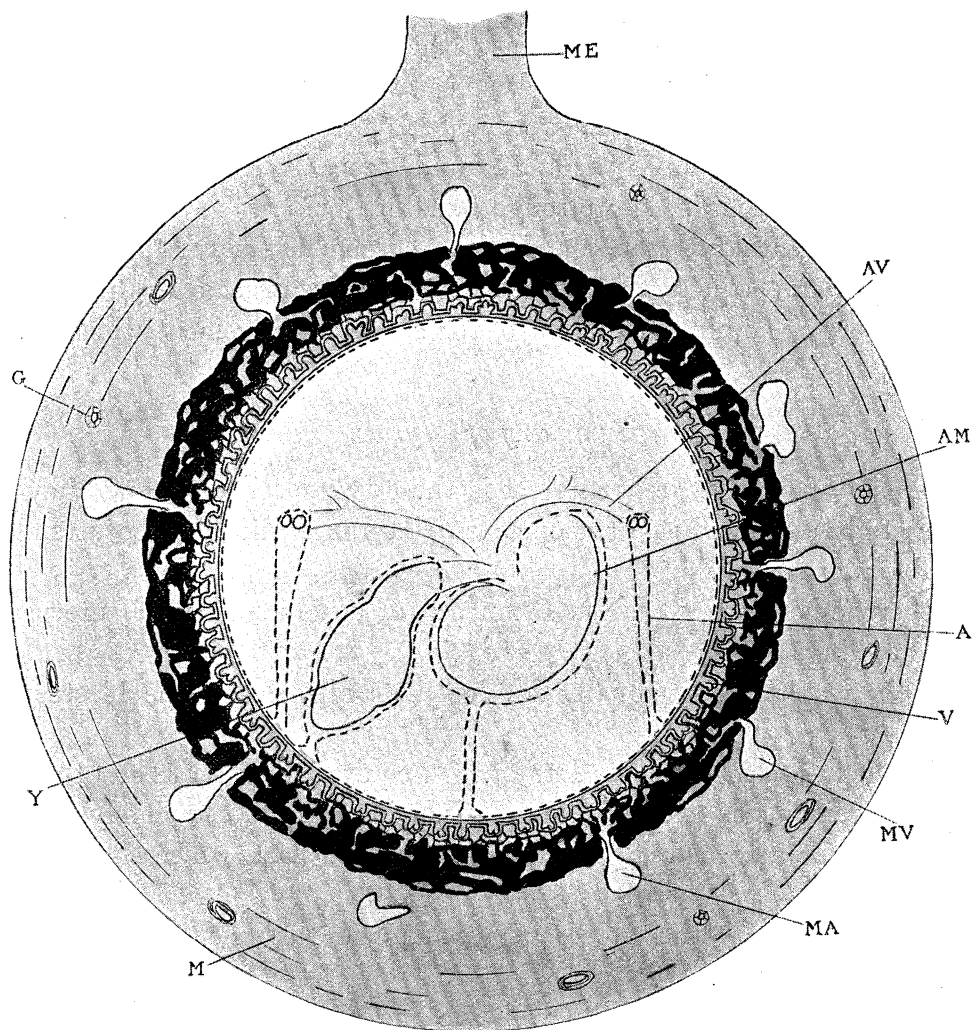
The allantois comes away easily from the trophoblast and is seen to be covered with short villi which fit into pits in the trophoblast. This is the distal wall of the allantois; on cutting through this a large hollow sac is entered which is the cavity of the allantois. This likewise surrounds the embryo. The blood vessels which pass from the umbilicus to the chorion are attached along their whole course to the proximal wall of the allantois, and do not partake of the enveloping process which has occurred in the allantois itself, so the cavity of the allantois is partly divided by bagging between these vessels (text-fig. 12 and fig. 30, Plate 11).

It is easy to see how such a condition can have come about on the supposition that the allantois of *Hyrax* is a hollow sac, and that it becomes early in contact with one part of the trophoblast: and subsequent expansion takes place so as to envelop the embryo, as one might imagine the folds of the inner net to pass through the trammels of a larger one, and so envelop whatever were below. Within this the amnion appears covering the embryo in the ordinary way.

Thus, there is a large allantoic cavity which is partially subdivided so as to form four sacs which meet below the embryo, but the cavities remain separated from each other by their respective walls. Above the embryo all are continuous. Presumably the yolk sac, which has become very much reduced in size, fig. 30, is enveloped.

So far as one can judge from sections of these two stages, unconfirmed by a study of the development, nearly the whole of the separated placenta consists of trophoblast.

Text-fig. 12 is a diagrammatic drawing of a section through the uterus, including the wall of the allantois. Commencing from the foetal surface there is the lining layer of hypoblast (A.), a very thin layer of squamous cells, the nuclei of which are not flattened. This layer is difficult to find in some places.



Text-fig. 12.—Transverse section through the uterus and foetus of Hyrax.

A, lining layer of allantois (hypoblast); AM, amnion; AV, allantoic blood vessels; G, uterine gland; M, muscle layer; MA, maternal artery; MV, maternal vein; ME, mesometrium; V, mesoblast of villus of allantois; Y, yolk sac, greatly reduced in size.

Then comes the allantoic mesoblast and somatopleur, a loose connective tissue with its foetal blood vessels containing nucleated deeply staining blood corpuscles.

The mesoblastic villi (V.) are blunt processes branching to a certain extent and carrying blood vessels.

Next comes the trophoblast, so I take it to be, which makes up the great bulk of the thickness of the placenta. It is a network of cubical cells in the meshes

of which is maternal blood. Close to the mesoblast the meshes are wide and the trophoblast is thinner; in the deeper layers the meshes are small. In fact the deeper the tissue the smaller the mesh, and at its base a different kind of tissue is found. This is less cavernous, stains more lightly, contains some very large nuclei, and shows less cell division.

The chief advance of this specimen beyond the first described one consists in the growth of the allantois so as to surround the whole embryo, and the development of the allantoic villi. These push against the spongy trophoblast, and become enveloped by the uprising trophoblastic lacunæ, now tense with maternal blood.

In some places there is blood between the trophoblast and the mesoblast. The trophoblast is here very much reduced, and probably the blood between the trophoblast and mesoblast is due to rough handling, or *post-mortem* changes, though it should be noticed that this occurs in *both* specimens (*vide* remarks on clots on p. 185). The villi are equally well developed over the ends as over the sides of the blastocyst. There is no hint at present of the zonary arrangement which is attained at full term.

Summary of Hyrax.

There are many points of great interest in these two specimens; and they tend to show that a study of the whole development of Hyrax is likely to be attended with much valuable information.

Firstly, there is no trace, so far as I can see, of any lumen of the uterus in any part of the swelling.

Secondly, the trophoblast is equally developed on all sides of the blastocyst, both end and sides.

Thirdly, at this—a comparatively late stage—equivalent to a 13- or 14-day rabbit, the trophoblast remains as a highly vascularised investment completely surrounding the embryo and not attached in any way to the mesoblast, which shows no sign of villous formation.

Fourthly, the glands of the uterus of this animal take no further part in the nourishment of the foetus.

For a considerable period both the yolk sac and allantois take nourishment from spongy trophoblast saturated with maternal blood to the embryo (text-fig. 11). Later the spreading of the allantois forces the yolk sac away from the trophoblast, after which the allantois is the sole intermediary between the trophoblast and embryo. Both allantois and yolk sac lie closely apposed but not in any way connected to the trophoblast layer. This inner surface of the trophoblast layer forms a cushion of thin-walled blood sinuses, containing, I suspect, arterial blood. The whole of the nutritive material for the embryo must at this time be derived from these sinuses, carried therefrom by the vessels of both allantois and yolk sac which lie in close *contact* but not with any protoplasmic connection.

From what I have written above and what we know in other cases about Hyrax and about other mammals, we may presume that the development of Hyrax is on lines somewhat like this—

Segmentation probably resembles that in *Erinaceus* and results in an early easily separated trophoblast, leaving the yolk sac as a complete vesicle. This is followed by the rapid thickening of the trophoblast on all sides, as indeed at first takes place in *Erinaceus* and in man. We should expect therefore an imbedding of the blastocyst and the formation of a decidua reflexa as in these forms. Of this, however, there is no sign.

I think there is clearly not such a reflexa formed as in *Erinaceus*, nor is a capsularis formed, as in some Rodents, accompanied by obliteration of the uterus lumen.

On the other hand the facts that the walls of the uterus are of equal thickness all round, and that there is an equally great sparseness of glandular tissue on all sides, rather suggest that the embryo does not sink into the mucosa at a very early stage like *Erinaceus*, *Cavia*, etc., but that it remains in the lumen of the uterus and, after attaining a considerable size and after a great increase of the trophoblast layer has been effected, it then becomes attached at all points at once to the walls of the uterus, from which it may have been for a long time separated by the presence of a thick and persistent zona or albumen layer.

The growth of the blastocyst appears to be accompanied by a great increase in the interglandular tissue of the stroma; for the few glands which are to be seen in the middle region of the swelling are all running parallel to the length of the uterus, and their openings are evidently at one end or the other of the pregnancy swelling.

In later stages of pregnancy the trophoblast with its blood supply seems to become much reduced, and the placenta is restricted to a comparatively narrow band, a good figure of which is given by GEORGE (36).

The dark spots seen in his figs. 87 and 88 forming a zone along the middle of the placental area of the uterus are no doubt the arterial and venous connections between the uterine vessels and the trophoblast lacunæ, which is just as one would expect from the condition found in my specimens.

The Elephant.

The placenta of the elephant, in so far as it is possible to gain a clear idea of it, has been described by Dr. STEVENS and myself in a paper recently published in the 'Quarterly Journal of Microscopical Science.*' I will therefore only add a few details and refer to the rest only so far as is necessary in a discussion on the comparative anatomy of the placenta of the Ungulates.

A point which I do not understand is the very well marked iron reaction obtained by the Macallum test in the villi which are lying up against the homogeneous mass

* 'Quar. Journ. Micr. Sci.' vol. 49, 1905.

covered with a well defined layer of cubical cells of trophoblast (*i.e.*, a cytotrophoblast).

Text-fig. 13 is a drawing of this region after treatment with hydrochloric acid and potassium ferrocyanide. Certain parts of the core of these villi are stained intensely blue. These stained parts are the walls of the capillaries. This possibly



Text-fig. 13.—Deposit of iron along the walls of foetal capillaries and basement membrane of trophoblast in Elephant half-term placenta.

L. Capillaries of Labyrinthine region; M. Basement membrane; V. Villus capillaries.

in fact only at certain places is there any deep penetration into the tissues of the mother after (in the sheep) disappearance of the uterine epithelium.

A comparison of the full term placenta in each case shows the resemblance (figs. 2 and 3, Plate 13).

I take first the condition of the sheep. Here as represented diagrammatically in fig. 2, Plate 13, we see the small chorionic villi which are to be found over the greater part of the intercotyledonary areas, and which do not penetrate the epithelium, but fit into depressions in the lining surface of the uterus.

At places, however, much longer greatly branched villi have penetrated the uterine tissues after disappearance of the epithelium and fit closely into deep crypts. These carry blood vessels which are separated from the maternal blood vessels by at least one continuous layer of trophoblast cells, a second but less complete layer of cells which are of foetal origin, and the endothelial wall of the maternal capillary, and usually some more maternal tissue.

At the base of the villi, that is to say, between the foetus and the mother, there is a system of spaces filled with extravasated maternal blood, into which folds and

seems to indicate that in this region a considerable absorption of iron from the mother is taking place. I have not been able to find any blood corpuscles in the homogeneous material as one would perhaps expect.

The placenta as a whole seems to me to admit of a very close comparison with that of the sheep, whereas, as we explained in the paper referred to, the resemblance to the carnivore type of placenta is more superficial.

Firstly, the allantois is large and vesicular, some portions of the cavity persisting till birth. So it is in the sheep.

Secondly, the whole surface of the blastocyst may develop short villi which fit into local depressions in the uterine walls (not into glands) and

processes from the chorion project. The cells of the trophoblast are here bathed in blood.

In the elephant we likewise have short villi over a large area, at any rate at half term, and certainly at full term at the poles (CHAPMAN). Whether these short villi penetrate the tissues we do not know for certain, but since these villi are in the half-term specimen covered with the same granular material which is not perforated by the larger villi at this stage, it is legitimate to suppose that they do not penetrate. Over one region, however, the villi are much longer, and at full term penetrate deeply the uterine tissues (ASSHETON and STEVENS (5)).

This we infer from the presence of large broken trunks in the after-birth.

Thirdly, there is a large mass of placental tissue made up of villi of the foetus and maternal blood channels.

This I believe to be comparable and probably homologous to the layer of blood sinuses filled with extravasated blood just alluded to in the sheep. (Figs. 2 and 3, Plate 13.)

In the elephant this process has led to an actual circulation being established in channels between the crowded foetal villi.

In the elephant the "deciduous" parts of after-birth seem to be formed by the gradual percolation of maternal blood among the crowded villi of the foetus. (Fig. 3, Plate 13, and compare with figs. 16, 18, and 22 in ASSHETON and STEVENS, and with my figs. 27 and 28, Plate 11, of sheep.)

The curious breaking-down of the trophoblast layer is noticeable in each.

These structural resemblances must have more weight in considering homologies than the general external form. Although the elephant may resemble the Carnivora in its zonary form of placentation, yet when we regard the structure of the placenta we find it differs in many respects therefrom, while it bears a striking resemblance to the ungulate type, more especially that of the sheep. Yet of all the cumulate types of placenta, it resembles that of the Carnivora most closely.

The part which at first sight appears to resemble the labyrinthine layer of the cat's or dog's placenta has no real similarity. (Compare figs. 3 and 4, Plate 13.) That such a condition as occurs in the elephant could be derived from the condition in the sheep is quite comprehensible.

It is clear that, from the shape of the cells in the trophoblast in the sheep where it is bathed by blood of maternal origin in the region under discussion (figs. 27 and 28, Plate 11), and also from the fact that many nuclei in this region show mitotic figures, this must be a region through which the foetus is gaining considerable nourishment.

Considering the very long period of gestation in the elephant, there is no great difficulty in conceiving how this part of the placenta of that animal may have arisen from the extravasation of blood between the mother and foetus. The chief difficulty is in conceiving how the circulation, which we must suppose to exist, is initiated.

In the elephant a large quantity of pigment is present in the syncytial layer (trophoblast) which lies between the foetal capillaries and maternal channels. This pigment is present as small spherical bodies, and is apparently got rid of by means of leucocytes (ASSHETON and STEVENS).

It is interesting to note that the same pigment occurs in the trophoblast cells in the sheep which occupy the position which I regard as homologous to this syncytial layer of the elephant. It occurs in the sheep also as minute particles upon the surface of small clear spheres. In the sheep, as in the elephant, it is insoluble in alcohol and ether. It is unaffected by hydrochloric acid and ferrocyanide of potassium, and is unstained by hæmatoxylin in water. These cells in which this pigment is formed are recognisable at quite an early stage. Although the elephant's placenta is more like that of the sheep than that of any other animal hitherto examined, still it bears some resemblance to the placenta of the Carnivora. The zonary nature is probably more the result of maternal peculiarities than of any special action on the part of the blastocyst, and seems here to be of little importance. To compare the two placentas, we must regard the labyrinthine layer of the Carnivora as being the homologue of the parts of the placenta of the elephant in which the long foetal villi penetrate the uterine tissues (as in the sheep, where the foetal villi penetrate the trophospongia) of the cotyledonary burr. The difference is that in the sheep the result of penetration is a series of crypts well separated, so that there is always a considerable amount of maternal tissue between neighbouring villi; whereas in the Carnivora the maternal tissues are reduced to the lining of the blood vessels. The plasmoditrophoblast is much more highly developed, and, by destroying all the maternal tissues except the blood vessel walls, it produces the "angioplasmode" of DUVAL.

From this it follows that the angioplasmode region of the Carnivora is in one sense to be regarded as the homologue of the cotyledonary burr of the sheep's placenta—although there is no approach to an angioplasmode, strictly speaking, in the sheep.

It should be remembered, however, that the cotyledonary burr, which is a special growth of interglandular tissue, is not represented as such in the carnivore placenta, where the uterine glands are present over the whole surface of the uterus.

These differences are chiefly due to the difference in the way in which the embryo attacks the uterus. In the Carnivora (according to DUVAL'S account) a distinct heaping up of the trophoblast occurs, which attacks the uterine tissues, and ultimately forms the angioplasmode.

The large blood lacunæ called the "poches choriales" and the "cavités de la bordure verte" filled with extravasated blood may be regarded as the homologue of the great tangle of maternal channels filled with extravasated blood, which go to make up the bulk of the after-birth of the elephant, and of the very much smaller extravasate lacunæ of the sheep.

In the elephant, however, the system is so ordered that a series of well-defined channels are formed in which, no doubt, there must be a constant circulation of blood.

Cow.

I have not made any research into the development of the cow's placenta, and have examined only a single stage, that of about the 12th week of pregnancy.

In this the cotyledons are large, measuring perhaps 30 millims. in diameter. They present, as is well known, a convex maternal surface, and are on stalks instead of being sessile and having a concave maternal surface as in the sheep.

The foetal villi and, consequently, the maternal crypts, are more regular than in the sheep and have every appearance of a more facile detachment at birth which is, I believe, the case.

They differ also in showing no patches of extravasated blood lying between the maternal surface and the foetal surface, as described above in the sheep, but this may possibly be a feature of development only in the later period of pregnancy. It may be noted, however, that in a stage corresponding to this the extravasated blood lacunæ are well established in the sheep.

The characters of the foetal villi are as follows: Each villus, which branches with considerable regularity but retains the main axis as the strongest stem is composed, as in the sheep, of a very loose gelatinous tissue with stellate cells and central artery, from which loops of capillaries pass into close contact with a superficial layer, the "trophoblast."

This trophoblast layer is, I think, a single layer of cells, but contains besides the more numerous cubical cells, which form the general covering, a large number of ovoid binucleate cells, which, although different in some respects, are probably the homologue of the large binucleate cells in the villi of the sheep.*

I may note here an important difference between the sheep and cow. None of the binucleate cells seem to be attached to the maternal tissue, that is to say, to the walls of the crypts. On the contrary, they are attached in most cases to the foetal villi, though in other places they lie in the shrinkage space between the villi and the crypts. Probably these latter have been torn off from the villi during the previous manipulation which the specimen has undergone. The whole of the crypts beneath the surface are lined by an even layer of cubical cells, which possess nuclei of rounded form and are very constant in size and appearance.

This layer of cells which clings to the walls of the crypts does not seem in any part to be fused with it, as do the cells which are always found at the fundus of each crypt in the sheep, for it shows in many places a tendency to be split off very much like a normal epithelium would split off (fig. 34, Plate 11).

In fact, I feel confident that here is a layer which is not represented as such in

* SELENKA (86) describes binucleate cells in the villus of *Tragulus*. Except for the presence of the binucleate cells, his account agrees more closely with KOLSTER'S, of the horse, than with mine, of the sheep.

the sheep; and it is far more epithelium-like than anything found in this position in the sheep.

A definite answer can only be given by a careful investigation of the development of the placenta of the cow.

In my single stage these lining epithelial-like cells are absent from the intercrypt superficial area.

C.—GENERAL CONCLUSIONS.

It is perhaps a bold course to attempt in a few pages a discussion of the differences and similarities between the various kinds of placentas, so far studied, and to give adequate reasons for suggesting new terms to indicate their morphological relationship to one another. Especially is it so since two attempts have been made quite recently with that end in view.

STRAHL, in HERTWIG'S *Embryology*, suggests a revision of the old terms deciduate and indeciduate, and ROBINSON, in the Hunterian Lecture of 1903, likewise objects to these names, but is no better pleased with STRAHL'S substitutes. TURNER (103) and HUBRECHT (45) many years before had pointed out the unsuitability of the terms as indications of a classification. Indeed anyone who has studied the recent work on the mammalian placenta must agree with these authors (so also with JENKINSON (53)) that the terms are now inappropriate, as the question whether some portion of the maternal tissue comes away with the after-birth, or whether it does not, no longer appears to be a matter of prime importance in determining the essential characters of the different types of placenta.

Moreover, a third alternative not contemplated when the terms deciduate and non-deciduate were introduced has become known, namely, the condition in which all or a large part of the foetal placenta is left within the uterus and undergoes absorption. To the third alternative the name of contra-deciduate has been given by HUBRECHT (50) and adopted by HILL (40).

The pig and mare, probably cow and cetacea, are typical examples of the indeciduata, and the placentas of these animals are probably quite non-deciduous, no part of the maternal tissue coming away at birth. The Carnivora are typical examples of the "deciduata" and their placentas are distinctly deciduous, maternal tissue is certainly lost during parturition. But how is it in the Sirenia (Dugong), Proboscidea, the Rodentia, Insectivora, Chiroptera, and Primates?

In the dugong, which is an indeciduate, apparently not only is no maternal tissue lost, but some of the foetal tissue remains attached to the uterus and is absorbed. So it is in the mole, while in the Rodents and Insectivores, undoubted deciduata, such as Erinaceus, Sorex and probably Primates, no maternal tissue except blood is lost at birth.

In many, *e.g.*, Sorex (HUBRECHT), guinea-pig, mouse, etc., a considerable amount of maternal tissue is destroyed during pregnancy. The sheep, as I have shown is, in

respect of the general type of placentation, indecuate; in respect of the loss of maternal blood, decuate; and in the retention of a large proportion of the trophoblast cells in the crypts, contra-decuate.

Clearly the terms *decuata* and *indecuata* are objectionable.

There is no adequate reason for retaining these terms as a description of class, and, since they are misleading, they should be dropped, though useful enough as descriptive of the placenta of any one species.

STRAHL proposes to substitute "halb-placenta" (or semi-placenta) and "voll placenta" (or placenta) in their place.

I agree with ROBINSON that these terms are not an improvement. It is a moot question whether we should call the one or the other the full placenta—for, after all, in point of success as an organ of nourishment only, the formerly-named indecuate placentas are the more successful. Compare, for instance, the young at birth of an Ungulate, with the young of a Carnivore, or even of the Rodents, Insectivores, or man.

ROBINSON's suggestion of "apposite" placenta for non-decuate and "conjoined" placenta for decuate, although getting rid of the objections to the old terms, does not, so it seems to me, strike at the root of the matter. He says: "the former (term) to indicate that the layers are merely in apposition, and can be separated without any necessary rupture or tearing, and the latter to indicate that the foetal and maternal sections of the organ are united together or conjoined."

I doubt very much whether there is more tearing of tissues in some of the Rodents than there is in the dugong or sheep at birth. And can we not with equal propriety—in fact, I think with greater consistency—describe the rat's after-birth as *apposed* as that of the sheep, in which there is very obvious interdigitation of villi?

All these terms refer to the condition at birth—or the relations of the after-birth to the maternal part of the apparatus.

As a result of a more thorough investigation into the development of the placenta of mammals, one perceives how great is the difficulty of differentiating between the various types, and how many are the resemblances which really exist.

Just in the same way as great difficulty is experienced by zoologists in forming a satisfactory classification of such groups as the Porifera, owing to the great diversity of characters, and yet abundance of connecting forms, so is there difficulty in the arrangement of the many types of placenta. As in sponges we have to be contented with a somewhat artificial classification, so, in arranging our placenta forms, we cannot give precise definitions of our types; but, nevertheless, an order of some sort is better than no order at all.

Some search should be made into the early differences which are fundamentally concerned in causing the later conditions. Of course, various causes lead to the many already known differences: such as the persistence or retention of zona, the presence of an albumen layer, the size of lumen, and nature of wall of the uterus, and presence

of specially prepared spots in uterus (trophospongiæ). For instance, the cotyledonary type of "non-deciduate" placenta would seem in some way to be due to the presence of the special interglandular areas—the caruncles which are present quite irrespective of pregnancy (cow, sheep)—and, therefore, is thus due to a special maternal character. A combination of maternal and foetal characters seems to determine the special form of placenta in the rabbit (ASSHETON (1)), while in others, *e.g.*, hedgehog, man, the special outward form or character appears to depend less upon the maternal than upon the foetal directive influences.

We should not look to the maternal part for any common cause—unless it be that of the detail of nourishment—but to the embryo. The Eutheria are characterised by a very marked similarity of their earliest stage of development. We should look to some feature which is concerned in the placenta formation which is common to all, and see if we can detect in this any early difference of behaviour which may afford us a character that can be regarded as fundamental.

Is there any one feature leading directly to the attachment of the embryo to the walls of the oviduct which is common to all the mammals? Obviously the answer is "Yes, the outer layer of the blastocyst, usually known now, thanks to HUBRECHT, by the term *Trophoblast*." That this is the organ of paramount importance was recognised years ago by MINOT, though under a different name, "chorion" (*vide* 'Human Embryology,' p. 377, and "Uterus-embryo," 'Journal of Morphology,' vol. 11, 1884). On p. 432 of the latter, he says: "As regards the evolution of the placenta, we are in the dark. Contrary to prevalent opinion, it is not an organ of the allantois, nor is it an organ of the yolk sac. On the contrary, it is always, so far as we know, an organ of the chorion, and begins its development by a differentiation of that membrane. The allantois is a secondary or later structure. Its primitive rôle is apparently only that of a stalk of connection between the chorion and embryo."

The last sentence, no doubt, is true of the ontogeny of the Primates and some others, but whether this represents the evolution of the placenta is another matter.

The allantois is the organ of respiration, and, to a certain very limited extent, of nutrition too (*i.e.*, water and albumen in Sauropsida), and, on the hypothesis that the mammalian ovum has been derived from a large yolked sauropsidan type, we can only suppose that it was due to the presence of the allantois that the placenta of mammals arose.

We see in marsupials an attempt at the formation of a placenta from the outer layer (trophoblast?) in *Phascolarctos* (CALDWELL (19)) (SEMON (88)), in *Didelphys* (OSBORNE (75)), *Dasyurus* (HILL (41)), *Hypsiprymnus* (SELENKA (84)); but it never comes to anything except in *Perameles* (HILL (40)), where it does become much more like the true placenta, and here it is in connection with the allantois.

I fail to understand MINOT's objection to considering the allantois an organ of the first importance in the evolution of the placenta. Still MINOT very rightly laid

stress upon the importance of the outer layer of the blastocyst, and about the same time HUBRECHT, who gave it the name of trophoblast, came to the same conclusion.

It has become more and more clear of recent years that whatever the form of placenta may be, whatever attachment may be brought about between foetus and mother, it is always initiated by means of the trophoblast cells, which either simply lie in close contact and tend to pierce (Pig (ROBINSON, 82)), or do pierce, the uterine epithelium as in Guinea-pig (SPEE (89)), Spermophilus (REJSEK (79)), Rabbit (ASSHETON (1), SCHOENFELD (83)), Hedgehog (HUBRECHT (45)), or bring about a general degeneration and disappearance of the epithelium, Mouse (BURCKHARD (18), SOBOTTA (117)), Sheep (ASSHETON), Carnivora (DUVAL (27)). In any case this is done by the trophoblast, and in most cases—but not in all—before the allantois is anywhere near the spot, or, indeed, even in existence.

Granted then that the trophoblast is of paramount importance in connection with the formation of the placenta, can we point to any differences in the behaviour of this fundamental layer which would serve as a basis of classification? I think we can.

Consider the condition of the trophoblast at the moment of its first entering into connection with the maternal tissues in such types as Erinaceus, Mus, some of the monkeys and presumably man on the one hand, and in pig, horse, sheep on the other.

In the former the trophoblast proliferates and forms a mass of tissue, into cavities in which subsequently maternal blood percolates (in a greater degree (Erinaceus, Mus, Primates) or in a less degree (rabbit, mole ?), while in the latter (pig, horse, cow) no such heaping up occurs, but a process of either simple folding (pig) or folding combined with ingrowth (sheep) takes place. In this latter there is a very slight suggestion of a heaping up, but the folding is by far the more evident cause of increase of surface.

This is a fundamental difference, marked from the earliest stages and leading to the two great types which have long been identified under the names “deciduate” and “indeciduate.” This difference may be expressed by such terms as *Placenta cumulata* and *Placenta plicata*.

The *Placenta cumulata* is the type of all those in which there is a distinct tendency to the formation of a heaping up of trophoblast cells among which spaces arise, into which maternal blood escapes and gives rise to subsequent maternal blood stream of the placenta. In most cases this is preceded by a differentiation of the heaped-up trophoblast (DUVAL's ectoplacenta, SELENKA's träger, etc.) into an inner (proximal) layer in which the cell boundaries are well defined, and an outer layer which is of a syncytial nature—the cytotblast and plasmodiblast of VAN BENEDEN respectively. This type always results in the temporary or permanent (during pregnancy) destruction of the uterine epithelium over some part of the area of the walls of the uterus.

The *Placenta plicata* is the type in which there is no such heaping up, and the general tendency of the trophoblast is to form folds. The uterine epithelium is in most cases left intact. But the characters of one type do not exclude absolutely the characters of the other.

I will take now some of the species of mammals, the development of whose placenta is sufficiently well known to enable me to classify them according to the above outlines.

The series is a fairly complete one, and no absolutely hard and fast line can be drawn at any one point. Thus we pass from the extreme plicate form of the pig's placenta through those of the mare, cetacean, cow, sirenian, sheep, elephant (all plicata) by way of the Carnivora to Chiroptera, Rodentia, Insectivora, and Primates (all cumolata).

The Mare.—A thorough investigation into the development of *Equus* and its placenta has yet to be made. From the works of TURNER (103), EWART (30), and KOLSTER (59), however, we know enough to show that the mare's placenta is clearly of the plicate rather than the cumulate type.

According to TURNER (103) in the placenta "at an advanced stage of pregnancy" the surface of the mucosa and the walls of the crypts were covered by an epithelium, which when examined *in situ* showed a polygonal pattern like the broad free ends of a columnar epithelium.

KOLSTER (59), who gives a figure of transverse section through a crypt and foetal villus, describes the epithelium lining the crypt as being much attenuated on the sides, but more evident at the fundus. It is perhaps worth while noting that this description seems to agree with that given in the foregoing pages for the sheep. But, nevertheless, I do not think this comparison is a proper one, for KOLSTER's fig. 11 shows a wide space between the layer and the villus, and this space is filled with secretion and contains numerous fat globules. There is nothing like this in the sheep. The presence of the secretion is strong evidence that the layer is uterine epithelium and not plasmodiblast.

KOLSTER describes the trophoblast covering of the villus as a single layer of cells whose boundaries cannot always be made out. TURNER says nothing about the covering layer of the villus.

EWART (30) has given an all too short account of the earlier stages in the development of the placenta in the mare. He tells us nothing about the covering of the villi at full term which are not formed till comparatively late (about the eighth week), but he gives some general account of the earlier stages.

Unfortunately he gives very few histological details. However, it is clear that the blastocyst is first attached, though very feebly, to the walls of the uterus by "some of the cells," which we must assume to be the trophoblastic layer, of the lower pole of the vesicle.

This he compares to a similar condition in the opossum. There is nothing in his

description to suggest that there is any heaping up of cells at this region. More likely the cells make connection as in the Pig (ROBINSON) or *Didelphys* (OSBORNE) or *Phascolarctos* (CALDWELL).

In the outermost portion of this region, which forms a ring, which corresponds in position with the sinus terminalis, the condition is intensified and gives rise to "delicate nearly parallel ridges" which aid in attaching the blastocyst to the mother. He does not say, however, whether there is any heaping up of the cells here. Presumably not; at least he describes another band which runs round his blastocyst rather higher than equatorially, which also helps in this rather precarious mode of attachment and which ultimately merges with the annulus at the lower pole.

EWART describes the formation of this zone thus: "Further, some of the cells forming the outer tissue or embryonic sac increase in length so as to form an indistinct belt or girdle, nearly on a level with the embryo."

Clearly there is no heaping up, and at a later period (five weeks) this girdle is said to consist "not merely of elongated cells, as at the end of the fourth week, but of numerous delicate folds separated from each other by deep furrows."

Witness also the description of the formation of the villi which occur only in the allantoic region. EWART says that this area "presents a countless number of minute dots. These dots, which are due to the elongation of small groups of cells, are the first indication of the coming nutrition processes or villi. Later a villus sprouts out in the position of each dot, the cells of the same forming a covering for the allantoic outgrowth in very much the same way as the finger of a glove covers a finger."

I think it is quite evident from the above quotations that the method of multiplication of the trophoblast cells tends to an expansion and consequently a subsequent folding and not to a heaping up of cells with blood lacunæ. KOLSTER also asserts there is no bleeding between the villi.

Cetacea.—Too little is known of the development of the cetacean placenta to enable one to speak with certainty. From TURNER'S papers we learn of the diffuse placenta that the chorion (*Orca*) is thrown into folds, and that the villi are "set in rows" and form parallel ridges. The villi fit into crypts which are lined by an epithelium.

Nothing is known of the early stages, and not much accurately of the histology of the chorion, for of *Orca*, TURNER says, on p. 480, "not only had several days elapsed after the death of the animal, but the chorion had soaked for some time in the warm water during the process of injection," and so he not unexpectedly failed to find any epithelium in the villi.

Although clearly in the later stages the cetacean placenta is of the plicate type, still there is no evidence at present whether the trophoblast is ever heaped up or not. The fact of the presence of folds, and of villi forming parallel ridges, suggests a folding tendency rather than a heaping, and no mention is made of any extravasated blood lacunæ.

Sirenia.—TURNER'S description of the advanced stage of the dugong does not suggest the occurrence of any heaping up. There are no lacunæ of extravasated blood, and the villi fit into crypts which are lined with an epithelium.

In one respect the dugong is unlike the majority of the plicate group in having some much longer villi than others which appear to remain within the crypts at birth and become absorbed. In this respect the dugong resembles the elephant.

Edentata.—Little is yet known of the early development of the Edentata. WEBER'S (111) account of some well-advanced stages in *Manis javanica* and *Manis tricuspis* indicates a plicate form. There are no lacunæ of extravasated blood, though in *M. tricuspis* the uterine epithelium degenerates locally, while in *M. javanica* there is evidence of the formation of a plasmodiblast comparable to the condition in the sheep.

The diagrams upon Plate 13 illustrate the general conclusions to which I have come with reference to the relation that the ungulate placenta bears to that organ in other orders of mammals.

In these figures the green colour represents maternal tissue, the uterine epithelium being indicated by the more vivid tone. The foetal tissues are in grey, buff, and black.

Only the placenta itself (except in one case) is shown, and is supposed to be seen in vertical section. The maternal blood vessels are indicated by white spaces outlined in red. These are in all cases surrounded by maternal tissue (green).

The bright vermilion masses are the lacunæ of extravasated maternal blood, which lie between the maternal and the foetal tissue in the plicate type and wholly within excavations in the trophoblast in the cumulate type, excepting just where the communication between the extravasated blood and the maternal system occurs.

The foetal blood system is not indicated at all.

Fig. 1 represents the condition in *Sus* (TURNER, ROBINSON, etc.). Here the glands take a prominent part in providing nourishment throughout foetal life and pour their secretion into special depressions in the placenta.

The uterine epithelium remains intact. There are no lacunæ of extravasated blood. The trophoblast is a single layer of cells, which, after the first three weeks, forms a syncytium. There is no differentiation into cytotrophoblast and plasmoditrophoblast. It is a typically *plicate placenta*.

This figure probably also represents the essential features of the placenta of *Equus* (TURNER(103), EWART(30)) of the Cetacea (TURNER(107)), the *Sirenia* (TURNER(108)) (though in this there seems to be the peculiarity mentioned above of the longer villi which remain within the crypts at birth), perhaps also some of the Edentata *Dasypus*, *Bradypus* (CHAPMAN(23), (24)), *Manis* (WEBER(111)), and possibly the Lemurs (TURNER(104), HUBRECHT(50) and STRAHL(42)), except *Tarsius*—if, indeed, a Lemur.

Fig. 2 represents the condition in the sheep. Here in correspondence with the presence in the uterus of certain special areas (*trophospongiæ*) the villi are restricted to those areas.

The glands, as in *Sus*, play an important part in the nourishment of the foetus throughout foetal life. The placenta is here also *plicate*, though a decided tendency to a proliferation or heaping of the trophoblast is exhibited at certain spots. Hence we can here differentiate between cytotrophoblast and plasmoditrophoblast. Extravasated blood occurs, forming lacunæ, which, however, lie between the mother and foetus, and not in spaces within a heap of trophoblast cells.

The epithelium of the uterus is destroyed where the foetal villi are, in which destruction the plasmoditrophoblast plays a leading part. The cells of the latter become later closely applied to and even in protoplasmic connection with the stroma cells of the uterus.

The sheep is at the extreme end of the series of plicate placentas and, by reason of the presence of this plasmodiblast layer, approaches the cumulate type.

The cow probably occupies a position between this and the foregoing (fig. 1). It is doubtful whether the epithelium of the uterus is lost, and there seems to be no extravasated blood, at least not enough to form lacunæ. On the other hand certain binucleate cells are present in the trophoblast, which may be homologous to those of the sheep (which I have spoken of as diplocaryocytes (*vide* p. 214)) and, if so, correspond to the plasmoditrophoblast of the cumulate type.

Fig. 3 represents the placenta of the elephant (ASSHETON and STEVENS) so far as can be determined from an after-birth at half term and one at full term.

Therefore the uterine part of the diagram is hypothetical. I know nothing of the condition of the uterine glands during pregnancy.

So also is the black layer at the tips of the central long villi. I have not conclusive evidence of its presence.

These cells, however, which must be regarded as plasmoditrophoblast, are undoubtedly present at the tips of the short lateral diffuse villi, and over the crowded bunches of villi which form the margins of the zonary band. (The zonary band is here supposed to be seen in transverse section.)

It will be noticed that the condition in the elephant resembles very closely that in the sheep, the chief difference being an enormous increase of extravasated blood region which goes to make up the great bulk of the after-birth.

It was this region which formerly was considered to correspond with the labyrinthine structure of the carnivore placenta. A glance at the next figure (4) will show how different it is.

The elephant's placenta is no more cumulate than the sheep's—it is essentially a plicate placenta. Probably an absence of special trophospongial areas in the uterus gives rise to a zonary rather than a cotyledonary general form.

Fig. 4 represents the carnivore placenta (DUVAL (27)), more especially that of the dog. Here there is an undoubted tendency to a heaping up of trophoblast cells which gives rise to the angioplasmode of DUVAL and ultimately to the "labyrinthine" region, a region to be compared with the part (A.) penetrated by the villi in the sheep or in the elephant.

Indeed, except for the actual heaping up of cells described by DUVAL, the general features of the carnivore placenta are those of the plicate type. For instance, the extravasation of blood into lacunæ resembles the condition in the sheep rather than that in the distinctly cumulate placenta like that of fig. 5, Rodentia (Mouse). The "bordure verte" and the "poches choriales" are more comparable to the lacunæ of the sheep than of the mouse.

Just as the sheep is at the extreme end of the series of plicate placentas nearest the cumulata, so the carnivore is on the border line near the plicata; for, in the ferret, according to ROBINSON'S (82) account of the development of that animal, the plasmoditrophoblast is reduced to a minimum, and STRAHL'S account of the placenta of the Carnivora, which differs very much from DUVAL'S, still more suggests the plicate character.

Perhaps the most striking difference between the carnivore and sheep's placenta is the fact that in the sheep there are special trophospongial areas which cause the polycotyledonary form. But these are strictly maternal structures, and the effect which a strictly maternal character has upon the forms of placenta does not seem to me to be of so fundamental a nature as characters of the trophoblast itself—the organ *par excellence* of placentation.

Close here the placenta of the Chiroptera must be placed. It is clearly cumulate, and by a breaking down eventually of the maternal tissue in the angioplasmode the maternal blood is left extravasated in the plasmoditrophoblast, a feature characteristic of the more perfectly cumulate types as in

Fig. 5, which is the placenta of a rodent such as mouse. (This figure is drawn from the placenta of *Acomys cahirinus*.)

Here there is considerable eating away of maternal tissue, both of the epithelium of the uterus and of the stroma cells, and the erosion is more general (JENKINSON (53)); and a very large heaping up of plasmoditrophoblast occurs, which becomes hollowed out into cavernous spaces into which extravasated maternal blood flows.

The very much folded appearance of the cytotrophoblast in this and fig. 6 is altogether a later occurrence, and is due more to a drawing out of tissue than a folding (due probably to the interaction of the two blood streams, foetal and maternal) and must not be confounded with early tendency of the trophoblast to expansion laterally (folding) on the one hand, and expansion vertically (heaping) on the other.

Fig. 6 illustrates a type in which the blastocyst becomes in one way or another embedded in the tissues of one side of the uterus. This type is always cumulate, and results in the formation of a decidua reflexa or capsularis.

In this particular case—Erinaceus—the trophoblast is heaped up all over, so also in Homo (PETERS (78)). In others, although they become embedded (Mus) the heaping up is from the first much more accentuated at, or round, the embryonal area, or confined to certain bands (Sorex) or certain spots, *e.g.*, Tarsius, Tupaia (HUBRECHT (46)), Semnopithecus, Hylobates (SELENKA (78)).

In the figure of *Hylobates* given by SELENKA the plasmoditrophoblast is reduced so much as to make the condition more comparable to that in the sheep than in a true cumulate type. However, so little has been hitherto made out about the youngest stages in the development of the trophoblast of the monkeys and man that we cannot theorise to much advantage. Such a form seems to show a possible connection between the strictly cumulate type of man and monkeys on the one hand, and the presumably plicate nature of the placenta of the Prosimians.*

A restriction of the area traversed by the allantois converts the diffuse or bell-shaped into the discoid placenta.

In Hyrax (typically cumulate) the early condition is clearly similar to that of man or Erinaceus, that is to say, the whole of the trophoblast is heaped up. In the former the allantois entirely surrounds the embryo and lines the whole inside of the blastocyst, and so the placenta is at first diffuse and subsequently becomes zonary. (metazonary?)

In the last named the allantois never extends far and a discoid placenta results.

In man and monkeys and *Tarsius* the allantois—or its equivalent the mesoblast—lines the whole blastocyst wall and a placenta, which so far as the embryo is concerned might be diffuse, is metadiscoid or doubly metadiscoid according to special conditions of the uterus walls and blood supply.

It seems to me that in classifying placentas we should take embryonic characters as the bases for the definition of our main groups, *e.g.*, the characters of the trophoblast, then the degree of distention of the allantois; while modifications produced by the purely maternal variation such as presence or absence of special trophospongiol areas, special vascular arrangements, and—on the supposition that it is formed by the *membrana granulosa* and not by the ovum itself—the *zona radiata*; and such additional coats as the albumen layer of the rabbit, must be of only subsidiary importance.

Wherefore the terms *placenta plicata*, and *placenta cumulata* which are based upon fundamental characters of the embryo are in my opinion preferable to others suggested.

The thick albumen layer round the rabbit's ovum is a good example of the effect a maternal special character has upon the form of the placenta. In this the cumulate character so evident in other rodents is reduced to a minimum, owing apparently to the large size attained by the blastocyst under special conditions before attachment to the uterus, together with the dissipation of the trophoblast from over the embryonal area, the special effects of almost purely mechanical causes.

The long persistent *zona* in the mole, *Talpa* (HEAPE) may have something to do with the diminution of the cumulate character which is characteristic of all other insectivores so far examined. It is distinctly cumulate, but resembles in some minor

* HUBRECHT (50) writes of *Nycticebus*, p. 60: "It is worthy of remark that the epithelium on the villi is in many places ever so much thicker and more considerable than what is found on the opposite maternal surface."

respects the character found in the sheep, more especially in the mode of destruction of the uterine epithelium and in the close application of the trophoblast to the maternal tissues (VERNHOOT (109)).

D.—EPITOME.

The following facts are the chief additions made in this paper to our knowledge of the morphology of the mammalian placenta :—

1. An account of the development of the placenta of a ruminant (the sheep) which is shown to occupy a position approximate to the deciduate type of placentation—

- (a) The trophoblast shows a distinct tendency to form two layers which are compared to the plasmoditrophoblast and cytotrophoblast of the deciduate type.
- (b) A destruction of the uterine epithelium takes place and no recovery is made over certain areas till after parturition.
- (c) A layer of foetal tissue (trophoblast) becomes applied to the maternal tissues in the cotyledonary areas which has hitherto been believed to be uterine epithelium.
- (d) A direct protoplasmic connection is effected between foetal and maternal cells.
- (e) Extravasated maternal blood forms lacunæ in which the shorter villi and bases of the longer villi lie bathed, thus leading up to a condition characteristic of the deciduate type.
- (f) The foetus is restricted to the lower part of the uterus, while the upper parts of the horns become specially active in secretion and even exhibit a general destruction of tissue to form pabulum.
- (g) At birth a large amount of foetal tissue is left within the uterus.
- (h) The sheep, as regards its placentation, is partly deciduate, partly non-deciduate, and partly contra-deciduate.

2. A revision of the terminology of placentas is proposed on the basis of the behaviour of the trophoblast layer of the embryo.

According to whether in the part it takes in the formation of the placenta it becomes *folded* or vertically *thickened*, the placenta is termed “plicate” or “cumulate.”

3. The anatomy of the elephant's placenta at half term and at full term is shown to be closely comparable to that of the sheep. It is essentially plicate, and its special peculiarities are easily derived from those of the sheep. Its most obvious difference, that is to say, the zonary as contrasted with the polycotyledonary form, is regarded as subsidiary in morphological importance to the histological and developmental characters.

4. On the ground of placentation the elephant may well be associated with the Ungulata, and has some features suggestive of the Sirenia.

5. Hyrax, on the other hand, is shown by its placentation to be in no way associated with the Ungulata vera or with the elephant. It is typically cumulate.

6. The zonary form of placentation in this case (Hyrax) is not to be compared with any other form of zonary placenta.

7. The placenta of Hyrax is remarkable for the highly developed diffuse placentation prior to the formation of the zonary form.

8. Taken as a whole, the paper indicates the true relation which the old, so-called, non-deciduous type bears to the deciduate type of placentation. The existence of a complete series between the extreme plicate type as seen in the pig and mare, and the extreme cumulate type, as seen in the hedgehog, man and Hyrax, by way of the types found in the cow, sheep, elephant, Carnivora, and Chiroptera is demonstrated, which conclusion is illustrated by the diagrams on Plate 13.

APPENDIX.

List of Sheep uteri examined for the purpose of this Paper.

Ovis.—Uterus and embryos. See list in my paper "Segmentation of the Ovum of the Sheep, etc."

	Length of blastocyst.	Length of embryo.	Length of villi (longest villus).
	millims.	millims.	millims.
Ovis 48. Non-pregnant	—	—	—
" 38. Two days	—	—	—
" 12. Three days	—	—	—
" 14. Six days	—	—	—
" 41. Six days	—	—	—
" 6. Seven days	—	—	—
" 34. Eight days ?	—	—	—
" 42. Ten days	—	—	—
" 20. Thirteen days	300	—	—
" 15. Fourteen days	—	—	—
" 27. Fourteen–sixteen days ?	—	—	—
" 28. Eighteen days ?	—	—	—
" 67. Nineteen days	360	7½	—
" 66. Twenty days	—	10	—
" 37. Twenty-five days ?	500 × ½ ?	15	0·1
" 47. Twenty-six–twenty-seven days ?	—	16	0·1
" 69. Thirty-one days	—	17	0·5
" 68. Thirty-five days	—	22	0·8
" 11. Forty-four days	—	32	1·0–2·2
" 45. Fifty days	—	44	2·3
" 12. Fifty-two days	—	50	4·5
" 46. Fifty-seven days	—	58	3 1
" 64. Fifty-six days	—	65	8·1
" 70. Seventy-eight days	—	220	9·0
" 65. Full term	—	Full sized lamb	10·0
" 71. After-birth	—	—	—

LITERATURE.

1. ASSHETON, R. "On the Causes which Lead to the Attachment of the Mammalian Embryo to the Walls of the Uterus," 'Quart. Journ. Micr. Sci.,' vol. 37 (1894).
2. *Idem.* "The Segmentation of the Ovum of the Sheep, with Observations on the Hypothesis of a Hypoblastic Origin for the Trophoblast," 'Quart. Journ. Micr. Sci.,' vol. 41 (1898).
3. *Idem.* "The Development of the Pig during the First Ten Days," 'Quart. Journ. Micr. Sci.,' vol. 41 (1898).
4. *Idem.* "An Account of a Blastodermic Vesicle of the Sheep of the Seventh Day with Twin Germinal Areas," 'Journ. Anat. Physiol.,' April (1898).
5. ASSHETON, R., and STEVENS, T. G. "Notes on the Structure and Development of the Elephant's Placenta," 'Quart. Journ. Micr. Sci.,' vol. 49, 1905.
6. BAER, VON. "Ueber Entwicklungsgeschichte der Thiere" (1837).
7. *Idem.* "Untersuchungen über die Gefässverbindung zwischen Mutter und Frucht in den Säugethieren," Leipzig (1828).
8. BALFOUR, F. M. "Comparative Embryology," 2nd ed., London (1885).
9. BENEDEN, VAN. "De la Fixation du Blastocyste à la Muqueuse Utérine chez le Murin (*Vespertilio murinus*)," 'Bull. de l'Acad. Roy. de Belgique,' 3me série, 15 (1888).
10. *Idem.* "De la Formation et de la Constitution du Placenta chez le Murin (*Vespertilio murinus*)," *Ibid.*
11. BONNET, R. "Ueber Syncytien, Plasmodien und Symplasma in der Placenta der Säugethiere und des Menschen," 'Denkschr. Med. Nat. Ges.,' Jena, vol. 10.
12. *Idem.* "Beiträge zur Embryologie der Wiederkäuer gewonnen am Schafei," Pt. 1, 'Arch. für Anatomie und Physiologie' (1884).
13. *Idem.* "Beiträge zur Embryologie der Wiederkäuer gewonnen am Schafei," Pt. 2, 'Arch. für Anatomie und Physiologie' (1889).
14. *Idem.* "Grundriss der Entwicklungsgeschichte der Haussäugethiere" (1891).
15. *Idem.* "Beiträge zur Embryologie des Hundes," 'Anat. Hefte,' vol. 20.
16. BONNET and KOLSTER. "Ueber die vergleichende Histologie der Placenta und die Embryotrophe der Säugethiere," 'Verhand. Anat. Ges.,' 16 Vers., p. 25.
17. BISCHOFF, L. "Entwicklungsgeschichte des Rehes," Giessen (1854).
18. BURCKHARD, G. "Die Implantation des Eies der Maus in die Uterus Schleimhaut und die Umbildung derselben zur Decidua," 'Arch. mikr. Anat.,' vol. 57, pp. 528-569 (1901).
19. CALDWELL, H. W. "On the Arrangement of Embryonic Membranes in Marsupial Animals," 'Quart. Journ. Micr. Sci.,' vol. 24.

20. CHAPMAN, H. C. "The Placenta and Generative Apparatus of the Elephant," 'Journ. Acad. Nat. Sci. Philadelphia,' vol. 8 (1880).
21. *Idem.* "Sur la Forme du Placenta de plusieurs Mammifères," 'C. R. Soc. Biol.,' Paris, vol. 55.
22. *Idem.* "Observations upon the Placenta and Young of *Dasypus sexcinctus*," 'Proc. Ac. N. Sc.,' Philadelphia, vol. 53.
23. *Idem.* "An Indeciduate Disco-Zonal Placenta in *Dasypus*," 'C. R. Soc. Biol.,' Paris, vol. 55.
24. CARUS, OTTO. "Erläuterungstafeln zur Vergleichenden Anatomie," 1826-43.
25. COSTE, J. J. "Histoire Générale et Particulière du Développement des Corps Organisés," Paris (1847).
26. DUVAL, M. "Le Placenta des Rongeurs," 'Journ. de l'Anat. et de la Phys.,' vols. 25-28 (1889-1892).
27. *Idem.* "Le Placenta des Carnassiers," *Ibid.*, vols. 29-31 (1893-1895).
Idem. "Études sur l'Embryologie des Cheiroptères," *Ibid.*, vols. 31-33 (1895-1897).
28. ERCOLANI, G. B. "The Utricular Glands of the Uterus," Boston (1880).
29. ESCHRICHT, D. F. "De Organis quæ Respirationi et Nutritioni Fœtus Mammalium inserviunt" (1837).
30. EWART, J. C. "A Critical Period in the Development of the Horse," London (1897).
31. FLEISCHMANN, A. "Entwicklung und Structur der Placenta bei Raubtieren," 'S. B. der kön. Preus. Akad. der Wiss. zu Berlin,' July (1891).
32. *Idem.* "Embryologische Untersuchungen: 3^{tes} Heft.—Die Morphologie der Placenta bei Nagern und Raubtieren," Wiesbaden (1893).
33. *Idem.* "Der einheitliche Plan der Placentarbildung bei Nagetieren," 'S. B. der kön. Akad. der Wiss. zu Berlin' (1892).
34. FRAENKEL. "Archiv für Gynaekologie," vol. 55 (1898).
35. FROMMEL. "Ueber die Entwicklung der Placenta von *Myotis murinus*," Wiesbaden (1888).
36. GEORGE, M. "Monographie anatomique des Mammifères du Genre Daman," 'Annales des Sciences Naturelles' (1874).
37. GÖHRE. "Dottersack und Placenta des Kalong (*Pteropus edulis*)," in SELENKA'S 'Studien über Entwicklungsgeschichte der Tiere. 5^{tes} Heft; 2^{te} Hälfte,' Wiesbaden (1892).
38. HEAPE, W. "The Menstruation of *Semnopithecus entellus*," 'Phil. Trans.,' B, vol. 185 (1894).
39. *Idem.* "The Menstruation and Ovulation of *Macacus rhesus*," 'Phil. Trans.,' B, vol. 188 (1897).
40. HILL, J. P. "The Placentation of *Perameles*," 'Quart. Journ. Micr. Sci.,' vol. 40 (1898).

41. HILL, J. P. "On the Foetal Membranes, Placentation and Parturition of the Native Cat (*Dasyurus viverrinus*)," 'Anat. Anz.,' vol. 18 (1900).
42. HERTWIG, O. "Handbuch der vergleichenden und experimentellen Entwicklungslehre der Wirbelthiere," Jena (1901-1905).
43. HOME, Sir EDWARD. "Lecture on Comp. Anat.," p. 328, Plate 27.
44. HUBRECHT, A. A. W. "Keimblätterbildung und Placentation des Igels," 'Anat. Anz.,' vol. 3 (1888).
45. *Idem.* "Studies in Mammalian Embryology. I.—The Placentation of the Hedgehog (*Erinaceus europæus*)," 'Quart. Journ. Micr. Sci.,' vol. 31 (1889).
46. *Idem.* "Studies in Mammalian Embryology. III.—The Placentation of the Shrew (*Sorex vulgaris*)," 'Quart. Journ. Micr. Sci.,' vol. 35 (1893-1894).
47. *Idem.* "Die Keimblase von Tarsius," 'Festschrift für Carl Gegenbaur,' Leipzig (1896).
48. *Idem.* "Ueber die Entwicklung der Placenta von Tarsius und Tupaia," 'Proc. of the Intern. Congr. of Zoology,' Cambridge (1898).
49. *Idem.* "Keimblattbildung bei Tarsius spectrum." 'Verh. 5 Intern. Zool. Congress'; "Furchung und Keimblattbildung bei Tarsius spectrum," 'Verh. Akad., Amsterdam,' Deel. 8.
50. *Idem.* "*Spolia nemoris*," 'Quart. Journ. Micr. Sci.,' vol. 36, 1894.
51. HUNTER, JOHN. "Essays and Observations," vol. 1 (1861), p. 198.
52. HUXLEY, T. H. "The Elements of Comparative Anatomy," London (1864).
53. JENKINSON, J. W. "Observations on the Histology and Physiology of the Placenta of the Mouse," 'Tijd. Nederl. Dierk. Ver.' 2, Dl. 7, pp. 124-198.
54. KAZZANDER. "Ueber die Pigmentation der Uterinschleimhaut des Schafes," 'Arch. f. Mikr. Anat.,' vol. 36 (1890).
55. KEIBEL, F. "Studien zur Entwicklungsgeschichte des Schweines (*Sus scrofa domestica*)," 'Morph. Arb.,' vols. 3 and 5 (1893-1896).
56. *Idem.* "Normentafeln zur Entwicklungsgeschichte der Wirbelthiere," Jena, vol. 18.
57. *Idem.* "Frühe Entwicklungstadien des Rehes," 'Verh. Anat. Ges. in Tübingen' (1899).
58. KLEBS, Professor E. "Comparative Anatomy of the Placenta," 'Arch. für Mikr. Anat.,' vol. 36 (1891), pp. 335-356.
59. KOLSTER, R. "Die Embryotrophe placentarer Säuger, mit besonderer Berücksichtigung der Stute," 'Anatomische Hefte,' vol. 18 (1902).
60. *Idem.* "Zur Kenntniss der Embryotrophe beim Verhandensein einer *Decidua capsularis*," 'Anat. Hefte,' vol. 22.
61. *Idem.* "Beiträge zur Kenntniss der Embryotrophe bei Indeciduatzen," 'Anat. Hefte,' vol. 20 (1903).

62. KOSSMANN, R. "Ueber die Anheftung des Discoplacentarier-Eies auf der Gebärmutterwand," 'Verh. D. Z. Ges.,' 13.
63. LEE, TH. G. "Notes on the early Development of Rodents," 'Amer. Journ. Anat.,' vol. 2.
64. MARCHAND, F. "Einige Beobachtungen an jungen menschlichen Eiern," 'Verh. Anat. Ges.,' 16 Vers., p. 177.
65. MARSHALL, F. H. A. "The Œstrous Cycle and the Formation of the Corpus Luteum in the Sheep," 'Phil. Trans., B,' vol. 196 (1903).
66. MARTIN, P. "Ein Pferdeei von 21 Tagen," 'Arch. für Thierheilk.,' vol. 32 (1890).
67. MAXIMOW. "Zur Kenntniss des feineren Baues der Kaninchenplacenta," 'Arch. für Mikroskop. Anat.,' vol. 51 (1898).
68. *Idem.* "Die ersten Entwicklungsstadien der Kaninchenplacenta," *Ibid.*, vol. 16 (1900).
69. MILNE EDWARDS. "Sur la Classification Naturelles des Animaux," 'Ann. des Sc. Naturelles,' vol. 1 (1844).
70. MINOT, C. S. "Die Placenta des Kaninchens," 'Biol. Cent.,' vol. 10 (1890).
71. *Idem.* "Uterus and Embryo," 'Journ. Morph.,' vol. 2 (1889).
72. *Idem.* "A Theory of the Structure of the Placenta," 'Anat. anz.,' vol. 6 (1891).
73. *Idem.* "Human Embryology," New York (1892).
74. NOLF. "Étude des Modifications de la Muqueuse Utérine pendant la Gestation chez le Murin (*Vespertilio murinus*)," 'Arch. de Biol.,' vol. 14 (1896).
75. OSBORNE, H. F. "Observations upon the Foetal Membranes of the Opossum and other Marsupials," 'Quart. Journ. Micr. Sci.,' (1883).
76. OWEN, R. "Description of the Foetal Membranes and Placenta of the Elephant (*Elephas Indicus*, Cuv.), with Remarks on the Value of Placental Characters in the Classification of the Mammalia," 'Phil. Trans. Roy. Soc.,' London (1857).
77. OWEN, Sir R. "Comp. Anat. Vert.," vol. 3, p. 736.
78. PETERS. "Ueber die Einbettung des menschlichen Eies," Leipzig und Wien (1899).
79. REJSEK, J. "Anheftung des Säugethiereies an die Uteruswand, insbesondere des Eies *Spermophilus citillus*," 'Arch. Mikr. Anat.,' vol. 63.
80. RESINK, A. J. "Bijdrage tot de Kennis der Placentatie van *Erinaceus europæus*," 'Tijd. Nederl. Dierk. Ver.,' Deel. 7.
81. ROLLESTON, G. "On the Placental Structures of the Tenrec (*Centetes ecaudatus*), and those of certain other Mammals; with Remarks on the Value of the Placental System of Classification," 'Trans. Zool. Soc.,' vol. 5 (1863).
82. ROBINSON, A. "Hunterian Lecture," 'Journ. Anat. and Phys.,' vol. 37 (1903).

83. SCHOENFELD, H. "Contribution à l'Étude de la Fixation de l'Œuf des Mammifères dans la Cavité Uterine, et des Premiers Stades de la Placentation," 'Arch. Biol.,' vol. 19.
84. SELENKA. "Studien über Entwicklungsgeschichte der Tiere. 1^{tes} Heft.—Die Keimblätter und Primitivorgane der Maus," Wiesbaden (1883).
85. *Idem.* "Studien über Entwicklungsgeschichte der Tiere. 3^{tes} Heft.—Die Blätterumkehrung im Ei der Nagetiere," Wiesbaden (1884).
86. *Idem.* "Studien über Entwicklungsgeschichte der Tiere. 5^{tes}, 7^{tes} Heft. 8^{tes} Heft. Entwicklung des Gibbon (*Hylobates* und *Siamanga*)," Wiesbaden (1899, 1900).
87. *Idem.* "Blattumkehr im Ei der Affen," 'Biol. Centralblatt.,' vol. 18 (1888).
88. SEMON, R. "Zoologische Forschungsreise in Australien," Jena, vol. 2 (1894).
89. SPEE, T. GRAF VON. "Die Implantation des Meerschweinchen Eies in die Uteruswand," 'Zeit. Morph. Anthropol.,' vol. 3.
90. SPIEGELBERG. "Lehrbuch der Geburtshülfe," 1878.
91. STRAHL, H. "Untersuchungen über den Bau der Placenta. I, II—Die Anlagerung des Eies an die Uteruswand," 'Arch. für Anat. und Phys., Anat. Abt.' (1889) and Supp.
92. *Idem.* "Untersuchungen über den Bau der Placenta. III—Der Bau der Hundeplacenta."
93. *Idem.* "Untersuchungen über den Bau der Placenta. IV—Die histologischen Veränderungen der Uterusepithelien in der Raubtierplacenta," *Ibid.* (1890) Supp.
94. *Idem.* "Untersuchungen über den Bau der Placenta. V—Die Placenta von *Talpa europæa*," 'Anat. Hefte,' 1^{te} Abt. 1 (1891).
95. *Idem.* "Ueber den Bau der Placenta von *Talpa europæa* und über Placentardrüsen," 'Anat. Anz.,' vol. 5 (1890).
96. *Idem.* "Zur Kenntniss der Frettchenplacenta," *Ibid.*, vol. 12 (1896).
97. *Idem.* "Neues über den Bau der Placenta," 'Anat. Hefte,' 2^{te} Abt. 6 (1896).
98. *Idem.* "Der Uterus gravidus von *Galago agisymbanus*," 'Schriften der Senckenberg. Naturf. Gesells. zu Frankfurt a. M.' (1899).
99. *Idem.* "Die Embryonalhüllen der Säuger und die Placenta," 'Hertwig Hand. d. Entwicklungslehre der Wirbelthiere' (1905).
100. *Idem.* "Zur Kenntniss des Placentarsyncytiums," 'An. Anz.,' vol. 21, p. 641.
101. TAFANI, A. "Sulle Condizioni Utero-Placentari della Vita Fetale," Firenze (1886).
102. TURNER, W. "The Placentation of the Sloths," 'Trans. Roy. Soc. Edin.,' vol. 27 (1873).
103. *Idem.* "Lectures on Comparative Anatomy of the Placenta," London (1876).
104. *Idem.* "Observations on the Placenta of the Lemurs," 'Phil. Trans.,' vol. 166 (1876).

105. TURNER, W. "On the Placentation of the Apes, with a Comparison of the Structure of their Placenta with that of the Human Female," 'Phil. Trans.,' vol. 169 (1878).
106. *Idem.* "On the Placentation of the Cetacea," 'Trans. Roy. Soc. Edin.' (1872).
107. *Idem.* "On the Placentation of Seals," 'Trans. Roy. Soc. Edin.' (1875).
108. *Idem.* "On the Placentation of Halicore Dugong," 'Trans. Roy. Soc. Edin.,' vol. 35 (1889).
109. VERNHOUT. "Ueber die Placenta des Maulwurfs (*Talpa europæa*)," 'Anat. Hefte,' 1^{re} Abt. 5 (1894, 1895).
110. WALDEYER. "Die Placenta von *Inuus nemestrinus*," 'S. B. der kön. Preuss. Akad. der Wiss. zu Berlin' (July, 1889).
111. WEBER, MAX. "Zoologische Ergebnisse einer Reise nach Niederländisch Ost-Indien," vol. 2, 1891.
112. WEBSTER. "Human Placentation," Chicago (1901).
-
113. ASSHETON, R. "On the Morphology of the Ungulate Placenta, etc.," 'Proc. Roy. Soc., Lond.,' vol. 76 B, 1905.
114. *Idem.* "On the Fœtus and Placenta of the Spiny Mouse (*Acomys cahirinus*)," 'Proc. Zool. Soc. Lond.,' 1905.
115. BENEDEN, E. VAN. "Recherches sur les premières Stades du Développement du Murin," 'Anat. Anz.,' vol. 16, 1899.
116. KEIBEL, F. "Die Entwicklung des Rehes bis zum Anlage des Mesoblast," 'Archiv für Anat. u. Phys.,' 1902.
117. SOBOTTA. "Die Entwicklung des Eies der Maus vom Schlusse der Furchungsperiode bis zum Auftreten der Amniosfalten," 'Arch. f. Mik. Anat.,' vol. 61, 1902.
118. STRAHL, H. "Zur Kenntniss der Placenta von *Tragulius javanicus*," 'Anat. Anz.,' vol. 26, 1905.
-

COMPLETE LIST OF REFERENCE LETTERS.

<i>All.</i>	Allantois.
<i>All. v.</i>	Allantoic vessels.
<i>Bl. v.</i>	Blood vessel.
<i>Cap. f.</i>	Fœtal capillary.
<i>Cap. m.</i>	Maternal capillary.
<i>Ch.</i>	Chorion.
<i>Chr.</i>	Fragments of chromatin.
<i>deb.</i>	<i>Débris</i> of maternal tissue.
<i>Ep.</i>	Epithelium lining uterus.
<i>Ep'.</i>	Epithelium cells of uterus undergoing absorption by the trophoblast.
<i>hy.</i>	Hypoblast.
<i>hyp. gl.</i>	Hypertrophied cells of a uterine gland.
<i>hyp. int.</i>	Hypertrophied interglandular cells.
<i>L.</i>	Leucocyte.
<i>leu.</i>	Leucocyte.
<i>M.</i>	Terminal part of intercrypt column (maternal) devoid of blood vessels.
<i>m. bl.</i>	Extravasated maternal blood.
<i>mat. b. v.</i>	Maternal blood vessel.
<i>mat. cot.</i>	Maternal part of cotyledon.
<i>mes.</i>	Mesoblast.
<i>mes. som.</i>	Somatic layer of mesoblast.
<i>pig.</i>	Pigment in broken down trophoblast.
<i>R.</i>	Ring bounding circular area of chorion which lies up against the opening of a uterine gland.
<i>Str.</i>	Stroma.
<i>Str. n.</i>	Nucleus of stroma cell.
<i>T.</i>	Diplocaryocyte.*
<i>Tr.</i>	Trophoblast.
<i>Tr. br.</i>	Broken down trophoblast.
<i>Tr. D.</i>	Diplocaryocyte (Plasmoditrophoblast).
<i>Tr. D.'</i>	Diplocaryocyte lining a maternal crypt.
<i>Tr. pl.</i>	Plasmodium formed by diplocaryocytes.
<i>T. sp.</i>	Spaces (lymphatic ?) in trophospongia.
<i>T. sp.'</i>	Dense layer of trophospongia.
<i>Vac.</i>	Vacuole in diplocaryocyte.
<i>V.</i>	Fœtal villus.
<i>Ys.</i>	Yolk sac.

* The term diplocaryocyte might be used for the doubly-nucleated cells which arise from the trophoblast and attach themselves to the uterine wall. Very rarely more than two nuclei may be present. There is no tendency to hypertrophy of the nucleus.

DESCRIPTION OF PLATES.

PLATE 9.

- Fig. 1. (Ovis 15.) Age 14 days. Section of part of the blastocyst, showing trophoblast and hypoblast. $\times 400$.
- Fig. 2. (Ovis 66.) Age 20 days. Transverse section through both uterine part and embryonic part of a cotyledon, showing the folds in the trophoblast and the sulci in the cotyledon in which the folds fit. The dark line indicates the very much broken uterine epithelium, together with the diplocaryocytes. $\times 97$.
- Fig. 3. (Ovis 67.) Age 19 days. Section through the thickened area of the trophoblast taken parallel to the ridges. The section shows that the trophoblast consists of two or three cells in thickness, and four more deeply staining cells, spherical in shape, three of which show two nuclei. Although the general trophoblast appears to be made up of several cells in thickness, yet many of the cells pass through the whole. $\times 400$.
- Fig. 4. (Ovis 67.) Age 19 days. Transverse section, showing the degenerating epithelium of a cotyledonary burr. The epithelium is seen to be separated by several trophoblast cells, which are probably derived from the trophoblast. $\times 400$.
- Fig. 5. (Ovis 67.) Age 19 days. A piece of epithelium from the cotyledonary burr of the uterus, showing a trophoblast cell (*Tr. D.*) $\times 400$.
- Fig. 6. (Ovis 67.) Age 19 days. A piece of the epithelium of the cotyledonary burr of the uterus. Trophoblast cell has now reached the base of the epithelium, and tends to separate the epithelium from the sub-lying stroma. $\times 400$.
- Fig. 7. (Ovis 66.) Age 20 days. A piece of the epithelium of the cotyledonary burr and of the trophoblast, a diplocaryocyte is seen to have just left the trophoblast layer, and to be forcing its way as a wedge between the uterine epithelial cells. It is very much deeper in colour than any other tissue. It shows the two nuclei, and a very distinct vacuole which is characteristic of these cells at this period. $\times 400$.
- Fig. 8. (Ovis 66.) Age 20 days. A piece of the epithelium of the uterus from the side of a cotyledonary burr, showing one of the trophoblast cells just entering the epithelium. It is much darker in colour than the epithelial cells, and contains three nuclei. $\times 400$.
- Fig. 9. (Ovis 66.) Age 20 days. Another piece of the epithelium from the side of a cotyledonary burr, showing an invading trophoblast cell. $\times 400$.
- Fig. 10. (Ovis 66.) Age 20 days. A piece of the epithelium of a cotyledonary burr, showing the complete penetration of the epithelium by a trophoblast cell (diplocaryocyte). $\times 400$.

- Fig. 11. (Ovis 66.) Age 20 days. Another portion of the epithelium of a cotyledonary burr, showing the arrival of the diplocaryocyte at the base of the epithelium. $\times 400$.
- Fig. 12. (Ovis 66.) Age 20 days. Another portion of the epithelium from the side of a cotyledonary burr, showing trophoblast cell beneath the epithelium. Its cytoplasm is very vesicular. $\times 400$.
- Fig. 13. (Ovis 66.) Age 20 days. Another portion through the blastocyst and uterine tissue near the centre of a cotyledon showing the process of destruction of the uterine epithelium. In the round mass (*Tr. D.*) I take the clearly marked nuclei to be of trophoblastic origin, and those (*Ep.*) which are obviously in an advanced stage of degeneration to be uterine epithelial cells undergoing destruction. $\times 400$.
- Fig. 14. (Ovis 66.) Age 20 days. Surface view of a cotyledonary burr, showing the sulci formed by the ridges already present on the blastocyst. $\times 5$.
- Fig. 15. (Ovis 69.) Age 31 days. A section taken through the distal end of a foetal villus and the uterine crypt. The foetal villus shows a core of loose mesoblastic tissue covered by a layer of ordinary trophoblast cells, and here and there a diplocaryocyte, the nuclei of which stain very deeply. The crypt is lined here and there by some darkly staining cells with darkly staining nuclei. These are to be regarded as having been derived from the trophoblast (diplocaryocytes). Certain of these near the base (*Tr. pl.*) show a connection between the cytoplasm and the strands of protoplasm of the stroma. The space between the villus and the crypt is an artifact due to great contraction of the mesoblastic core of the villus which, in the natural state, is gelatinous.
- Fig. 16. (Ovis 68.) Age 35 days. A section taken longitudinally through one of the crypts and the apex of a villus. The crypt is completely lined by a layer of trophoblast cells, some of which are in protoplasmic connection with the stroma cells. The double nucleate condition is seen at the two corners. Diplocaryocytes, also on the point of budding off, are seen on the villus. The trophoblastic cells are in close contact with the capillaries of the stroma. $\times 400$.

PLATE 10.

- Fig. 17. (Ovis 66.) Age 20 days. Stained with borax carmine and picronigrosin. Section through the wall of the blastocyst and uterine tissue of a cotyledon; the uterine epithelium has been entirely absorbed; the few brightly staining nuclei lying in loose vesicular cytoplasm are the diplocaryocytes, which now form an irregular plasmodial layer over the stroma. $\times 400$.
- Fig. 18. (Ovis 11.) Age 49 days. One of the patches of the villi on the chorion

in the region of the embryo ; the ridges and furrows running transversely are very conspicuous. $\times 10$.

- Fig. 19. (Ovis 11.) Age 49 days. Section taken longitudinally through the apex of a foetal villus. Various stages in the formation and separation of the diplocaryocytes can be seen. $\times 400$.
- Fig. 20. (Ovis 11.) Age 49 days. A section taken longitudinally through the base of a crypt. A doubly nucleated cell appears, clearly forming part of the protoplasmic lining of the crypt. $\times 400$.
- Fig. 21. (Ovis 47.) Age 26 days? A piece of the cotyledonary burr showing the development of the blood vessels and lymphatic spaces close to the surface. Little pieces of the trophoblast are seen in places. The lower part of the figure shows the original stratified condition of the stroma through which the capillaries run perpendicular to the general surface. It is above this area, that is to say in the more superficial part of the cotyledon, that the blood vessels and lymphatics are developing. $\times 400$.
- Fig. 22. (Ovis 11.) Age 49 days. Transverse section through the fundus of the crypt at an early stage ; the stroma cells are very much vacuolated, the trophoblast cells of the embryo line the fundus of the crypt and tend to work their way in between the cells and the stroma. $\times 450$.
- Fig. 23. (Ovis 45.) Age 44 days. A section passing through the base of one of the foetal villi, showing the expanded outer end of the intercrypt columns of the cotyledon. The surface of these terminations of the columns are traversed by wide blood vessels. The destruction of these blood vessels probably leads to the extravasation of blood at a later period. $\times 97$.
- Fig. 24. (Ovis 65.) Age full term. A piece of the epithelium of the gland showing leucocyte at the base of the epithelium. $\times 450$.
- Fig. 25. (Ovis 65.) Age full term. Stain thionin, eosin and orange. A portion of the trophoblast at the base of a villus, where it is bathed in maternal extravasated blood, which shows the character of the diplocaryocytes and the way in which they take their origin at the base of the trophoblast and work their way outwards. As they reach the surface the nuclei become contracted and degenerate. $\times 500$?
- Fig. 26. (Ovis 65.) Age full term. A section taken through a piece of the wall of the upper part of one of the horns of the uterus. Both the glandular epithelium and the interglandular tissue are undergoing a process of hypertrophy followed by desquamation. All the sections of glands show *débris* within their lumina. Large numbers of leucocytes, *débris* of cells and grains of chromatin, fill the cavity of the uterus. $\times 200$.

PLATE 11.

- Fig. 27. (Ovis 65.) Age full term. Section taken vertically through the foetal side of a cotyledon. The lower part of the section shows the chorion with blood vessels. The trophoblast is thrown into folds and on the left side is continued over a villus which contains blood vessels. Large lacunæ of extravasated maternal blood bathe the folds of the trophoblast and the bases of the villi. The maternal tissue stains a more orange tint than the foetal tissues and the nuclei are smaller and flattened. There is very little trophoblast lining the maternal tissues in this region. The large irregular piece of maternal tissue which lies between the folds of the trophoblast shows no sign of a covering of trophoblast and is almost quite devoid of nuclei. $\times 400$.
- Fig. 28. (Ovis 65.) Age full term. A small portion of a region corresponding with that of the above section, under a higher power. This shows the tendency to a breaking up of the trophoblast where the folds lie in contact with each other. Large pigment granules are scattered in little masses throughout the folds. At one corner the section passes through one of the lacunæ of extravasated blood. Where the trophoblast cells are in contact with this blood there is no sign of breaking up, each cell is clearly defined, with nucleus, and with a sac-like termination which stretches out into the blood lacuna. $\times 400$.
- Fig. 29. (Ovis 65.) Age full term. A transverse section of a small piece of the chorion epithelium showing the capillaries of the chorion lying close against the epithelium, and the sac-like terminations of the epithelial cells. $\times 900$.
- Fig. 30. (Hyrax.) (*Procavia capensis*.) A figure of the blastosphere of Hyrax removed from the walls of the uterus and laid open. The thick outer layer is the trophoblast, within which the allantois is seen to be closely lining the trophoblast. From the allantois to the embryo four main vascular trunks converge and, together with the yolk sac which lies to the left of the embryo, disappear into the embryo. $\times 5$.
- Fig. 31. (Sus 31.) Age $4\frac{1}{2}$ days. A portion of the epithelium and stroma of the uterus of the pig. $\times 400$.
- Fig. 32. (Sus 15.) Age 16 days. A portion of the epithelium and stroma of the uterus of the pig at a later date showing a degeneration in the epithelium. $\times 400$.
- Fig. 33. (Sus 7.) Age 20 days. A section taken through the wall of the uterus and the wall of the blastocyst. Below is the stroma of the uterus lined by a regenerated epithelium consisting of long thin columnar cells with convex outer surfaces. Closely lining this is the trophoblast of the

blastocyst, which is a syncytium, and fits closely in between the tops of the uterine epithelial cells. A blood vessel is cut across and shows the large nucleated foetal corpuscles. $\times 400$.

- Fig. 34. (Bos 1.) Age uncertain. A section taken through a fundus of crypt of one of the cotyledons showing a portion of the villus within it. The cells lining the crypt are epithelial in appearance, and show no sign of forming a syncytium or of connection with the adjoining stroma cells. In the villus are seen two kinds of trophoblast cells, ordinary cubical cells and large deeply staining doubly nucleated cells (diplocaryocytes). $\times 400$.

PLATE 12.

- Fig. 35. (Ovis 66.) Age 20 days. Stained with borax, carmine, and picro nigrosin. Section through the wall of the blastocyst and uterine tissue of a cotyledon showing destruction of the uterine epithelium. The brightly stained nuclei (*Tr. D.*) are the nuclei of those cells which have migrated from the trophoblast, forced their way between the epithelial cells, and are now lining the uterine stroma. The masses (*Ep.*) are the remains of uterine epithelium rapidly undergoing disintegration. The dark staining cell with bright nucleus and a vacuole is one of the diplocaryocytes just attacking that piece of epithelium. $\times 400$.
- Fig. 36. (Ovis 66.) Age 20 days. Stained with hæmalum, thionin, orange G. A section taken near the centre of a cotyledon, showing very clearly the conspicuous character of the diplocaryocytes. Most of the ordinary trophoblast cells, which have nuclei which show very little chromatin, have their cytoplasm filled with long bodies stained yellow, probably of proteid nature. $\times 400$.
- Fig. 37. (Ovis 12.) Age 52 days. A section taken longitudinally through the middle of the cotyledonary area. The stroma cells are darker in colour and are lined by a very irregular layer of trophoblast cells. In the middle is a section through one of the villi taken close to the surface so that only the epithelium is cut through. The diplocaryocytes are recognised by the more deeply staining quality of their nuclei, and by the fact that the protoplasm is drawn away from the general surrounding tissue. $\times 400$.
- Fig. 38. (Ovis 12.) Age 52 days. A highly magnified section through the base of one of the crypts showing the plasmodium formed by the trophoblast cells; the strands, processes of protoplasm, are seen to be in direct connection with the cells of the stroma. $\times 900$.
- Fig. 39. (Ovis 65.) Age full term. A section taken vertically through the inner part of a cotyledonary area showing the interlocking of the foetal and

maternal tissues. The foetal tissue shows a large blood vessel which occupies nearly the whole of the villus. From it small capillaries run out at right angles, and are covered by a layer of trophoblast. These fit into little crypts, which are lined by the trophoblast syncytium, the cells of which stain more deeply. Many of the nuclei are shrivelled and in a state of degeneration. $\times 400$.

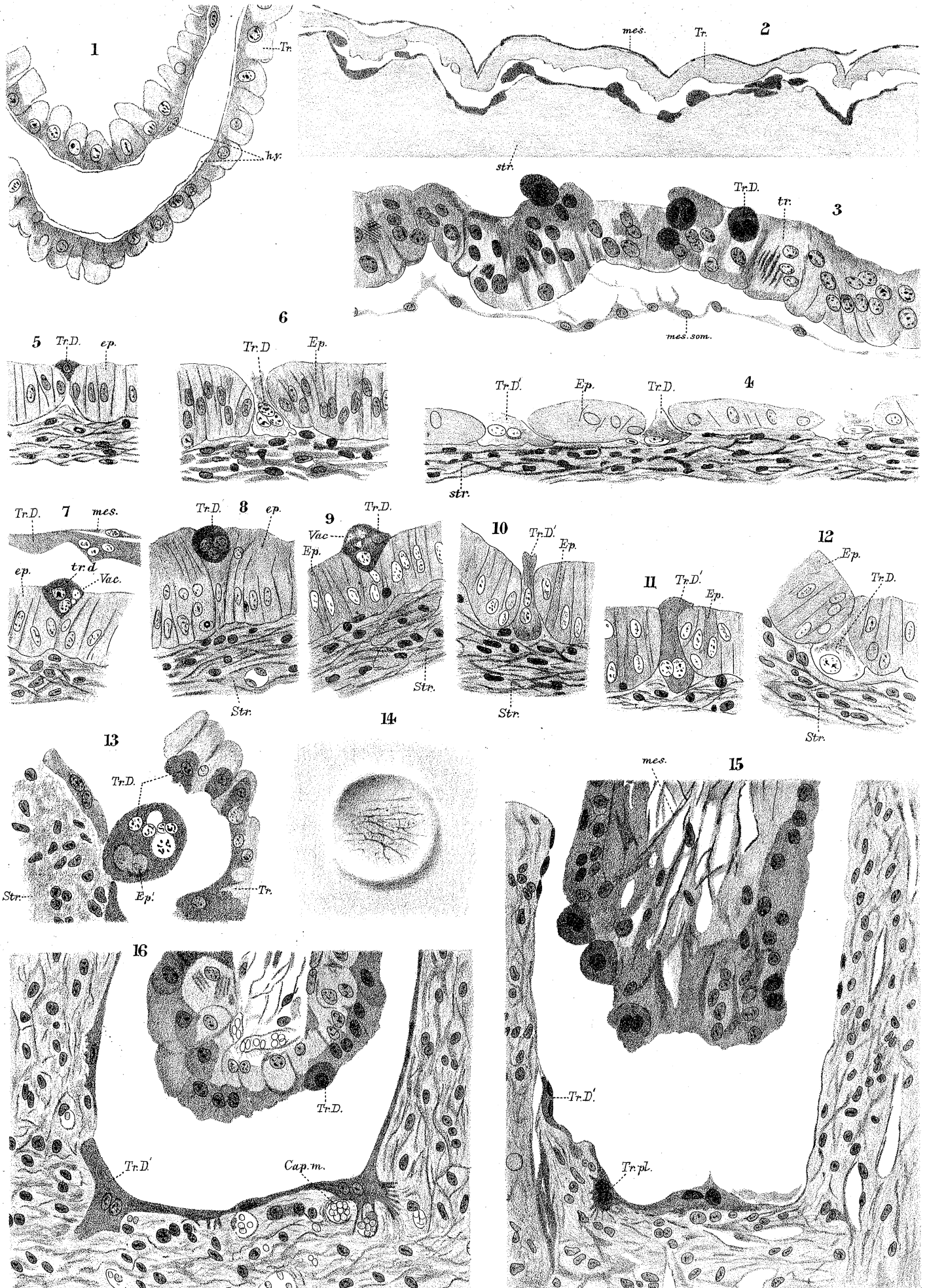
- Fig. 40. (*Ovis* 65.) Age full term. Section through the base of a crypt and apex of a villus. The foetal blood vessels are seen to run close to the surface of the villus, the crypt is lined by a thick plasmodial layer derived from the diplocaryocytes of the embryo. One diplocaryocyte is seen on the point of detachment from the villus to join the plasmodium. $\times 400$.

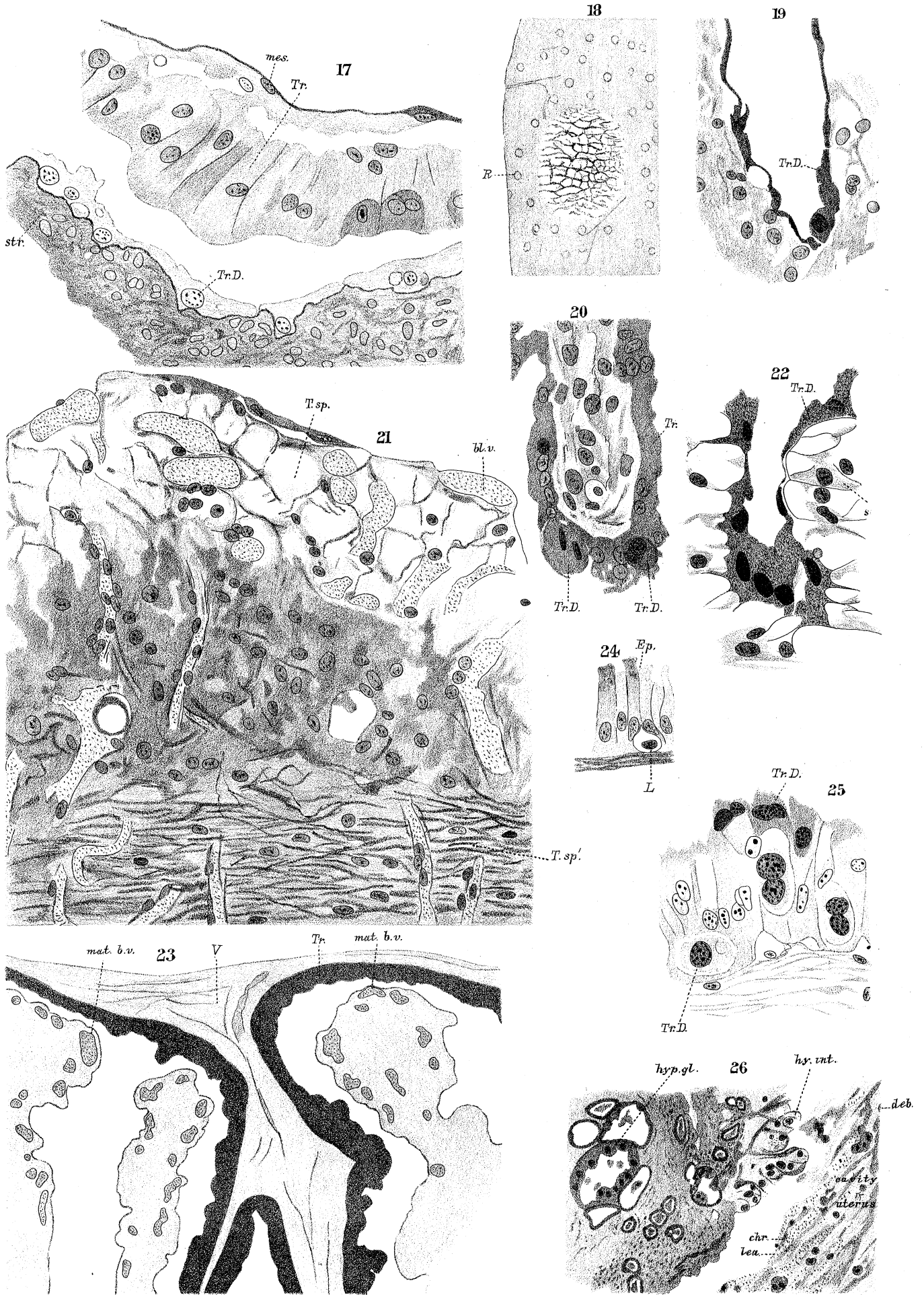
PLATE 13.

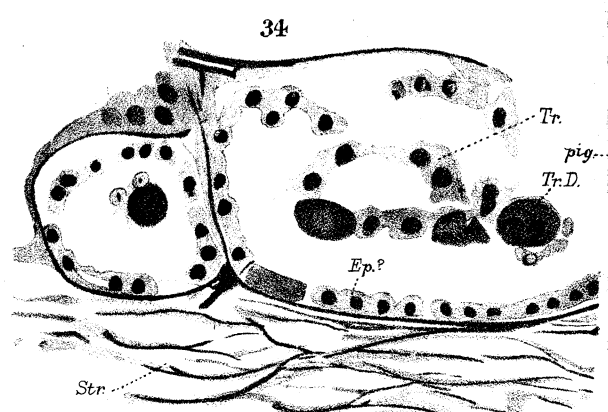
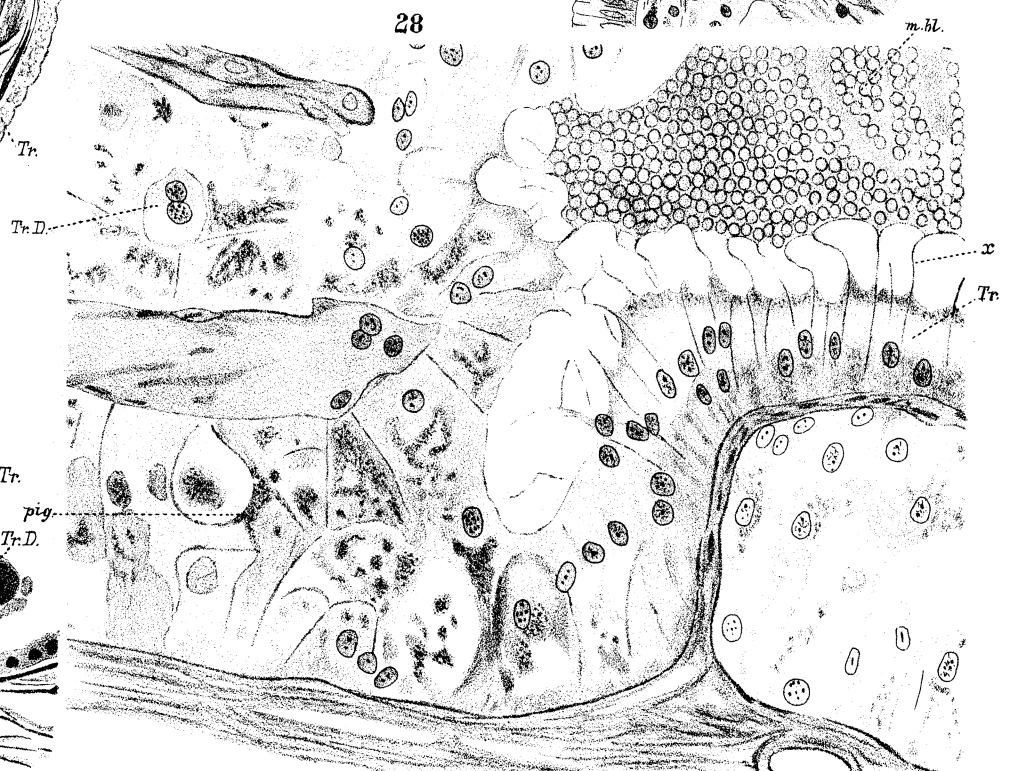
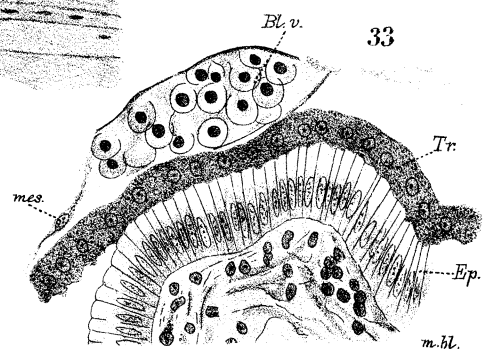
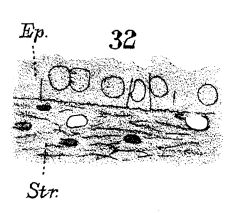
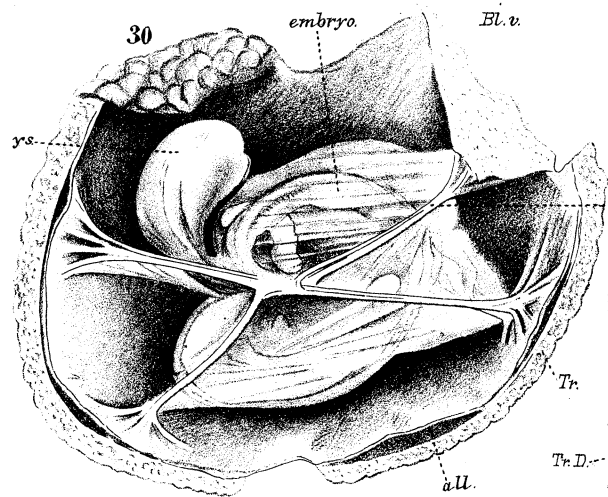
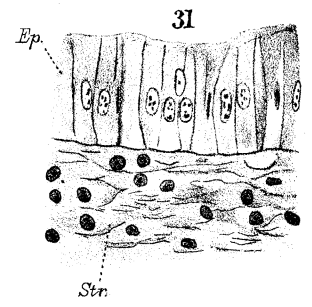
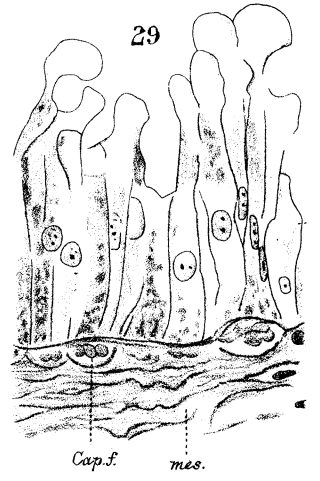
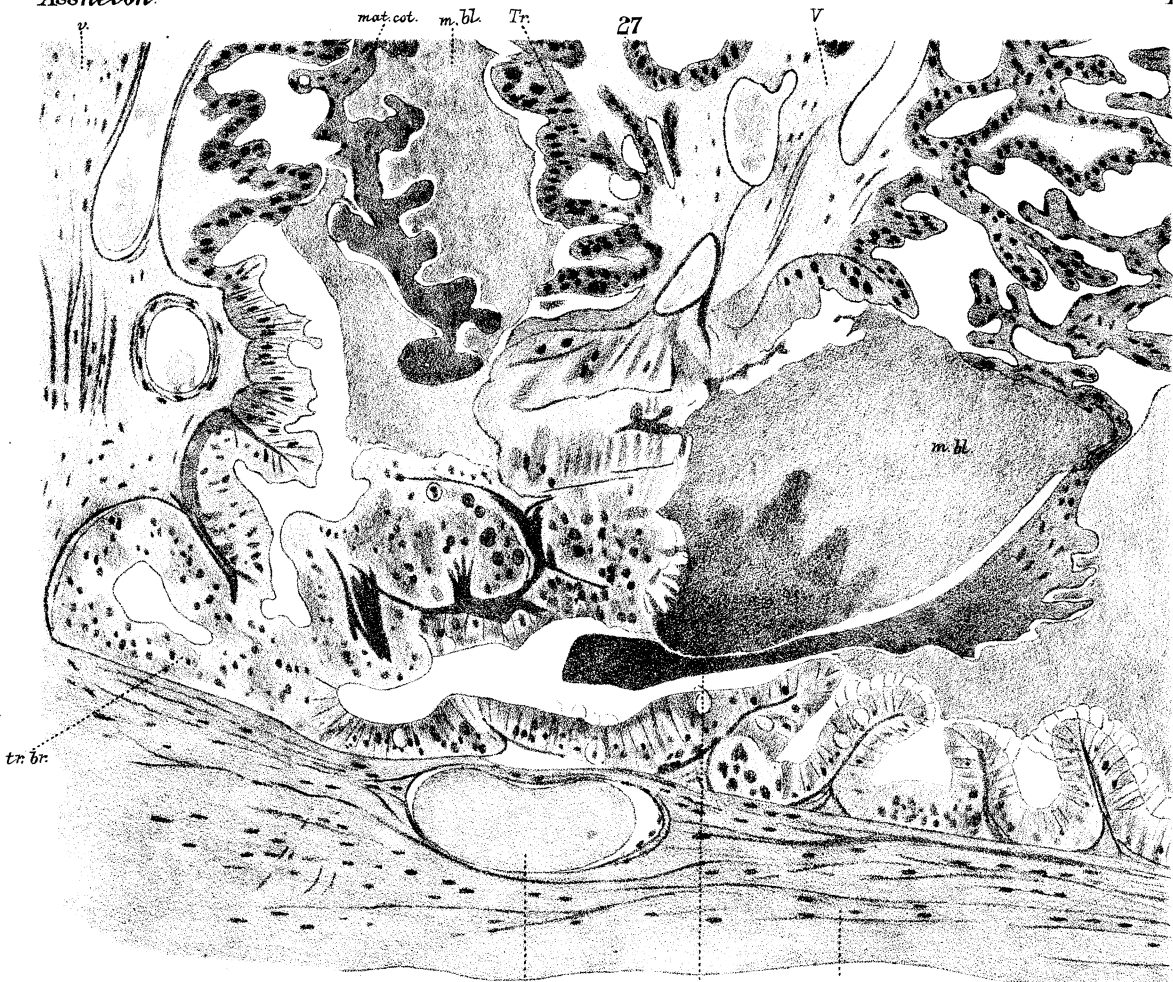
Diagrams to illustrate the relations of the placenta of the Ungulata Vera and Sub-Ungulata to that of the cumulate type, as exemplified by *Acomys* and *Erinaceus*.

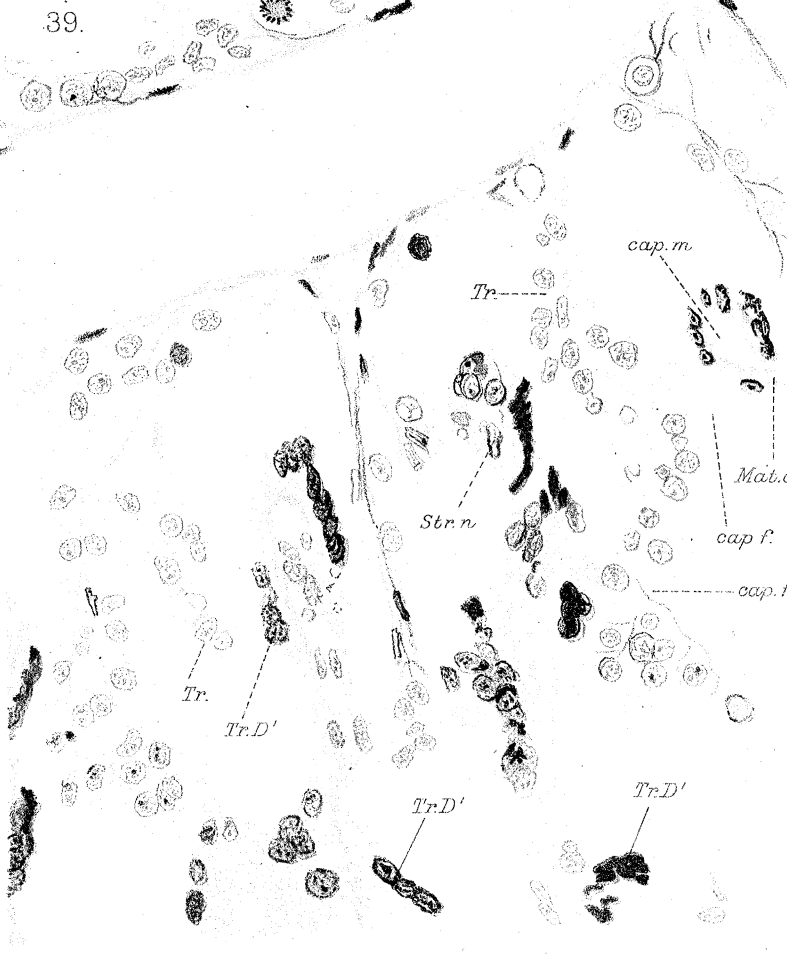
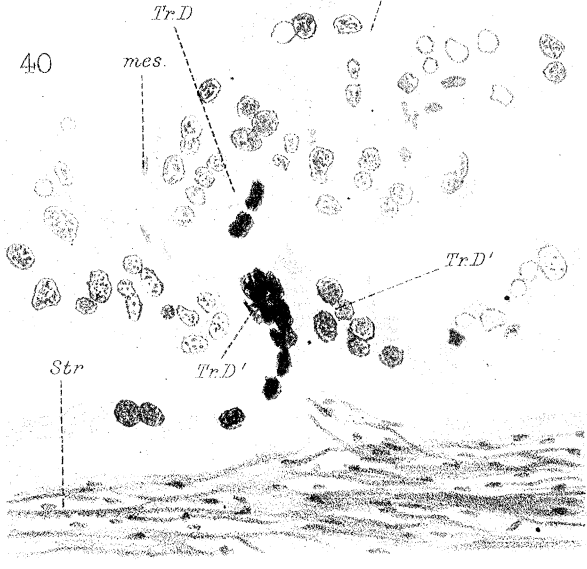
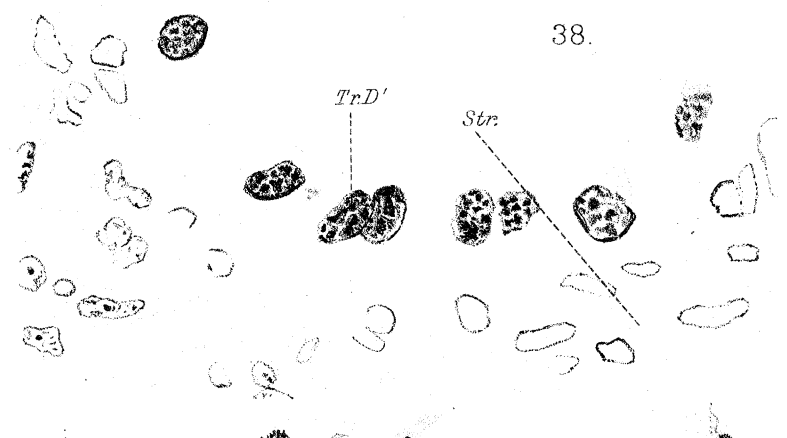
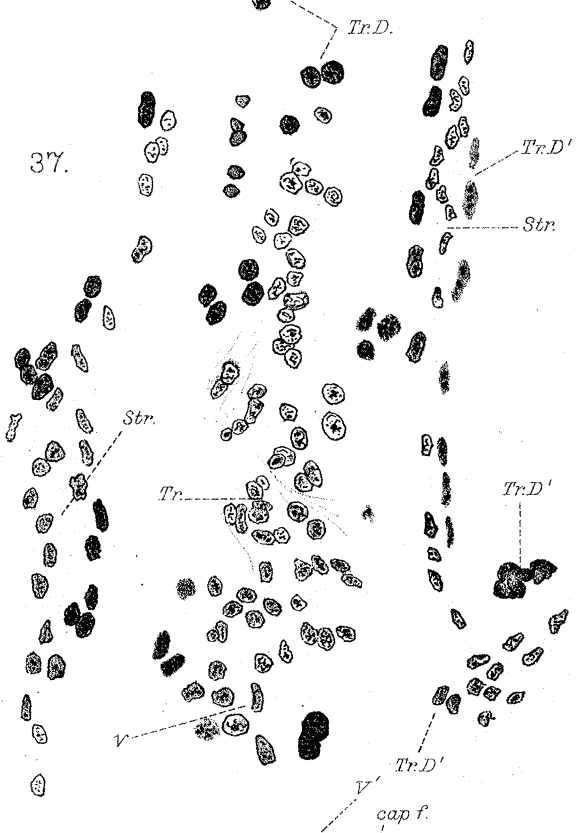
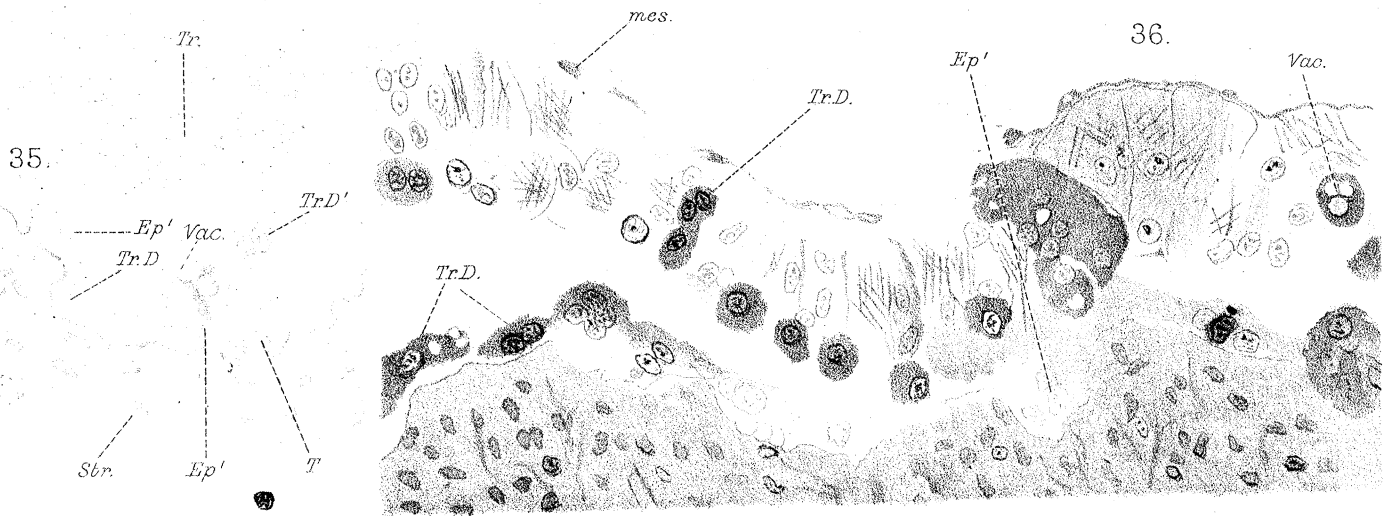
Maternal tissues are in green, except maternal blood, which is vermilion. A white space bordered by vermilion is maternal blood vessel; masses of vermilion are lacunæ of extravasated maternal blood. Plasmodiblast is black, cytoblast is blue, foetal mesoblastic tissues stone colour.

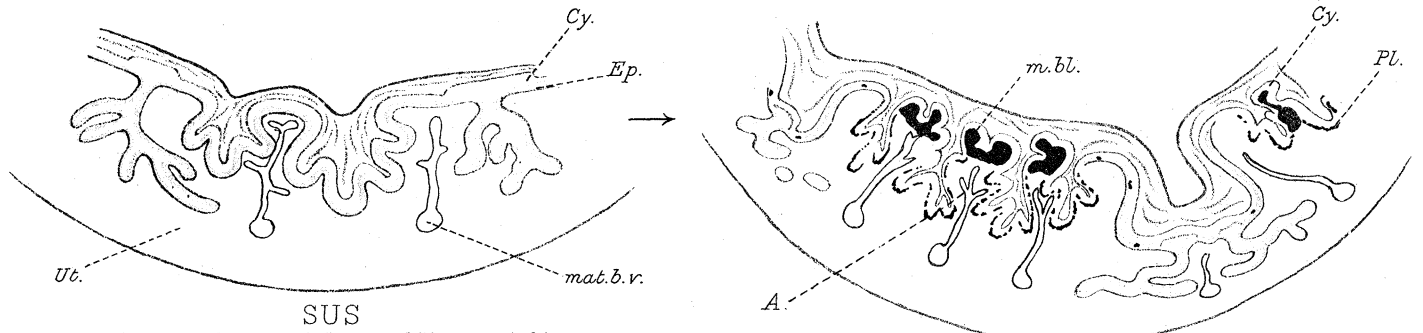
- Fig. 1. (*Sus*.) Plicate. There is no permanent destruction of uterine epithelium. There is no extravasated maternal blood. The uterine glands pour secretion on to special circular areas of the chorion.
- Fig. 2. (*Ovis*.) The placenta is clearly on the same plan as above; but at certain points a slight thickening occurs of the trophoblast, at which spots the uterine epithelium is destroyed. There are small lacunæ of extravasated maternal blood. Plicate.
- Fig. 3. (*Elephas*.) Half-term placenta. It differs little in essential features from *Ovis*. The most important is the great development of the extravasated blood lacunæ between the folds of the subzonal membrane (or of chorion), which, no doubt, result in a well-established circulation. At the borders the mode of development of the system is shown where the blood is seen to be penetrating between the closely-packed foetal folds. The condition of glands is not known. Plicate.
- Fig. 4. (*Canis*.) The lacunæ are more evident than in *Ovis*, but probably do not form part of the regular circulatory system. By a greater accumulation of plasmoditrophoblast, a nearer approach to the cumulate type is attained.
- Fig. 5 (*Acomys*) and Fig. 6 (*Erinaceus*) are cumulate. The trophoblast, greatly thickened, is honeycombed by lacunæ in which maternal extravasated blood circulates. The importance of the glandular secretion is greatly diminished.
-





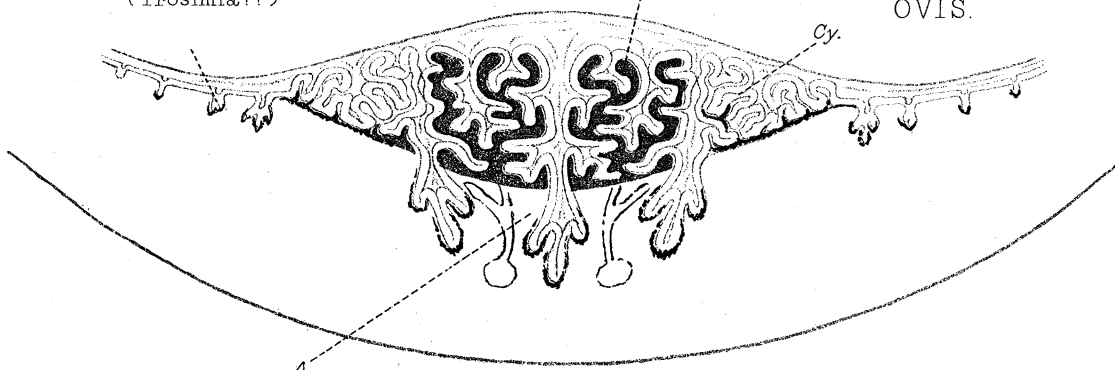




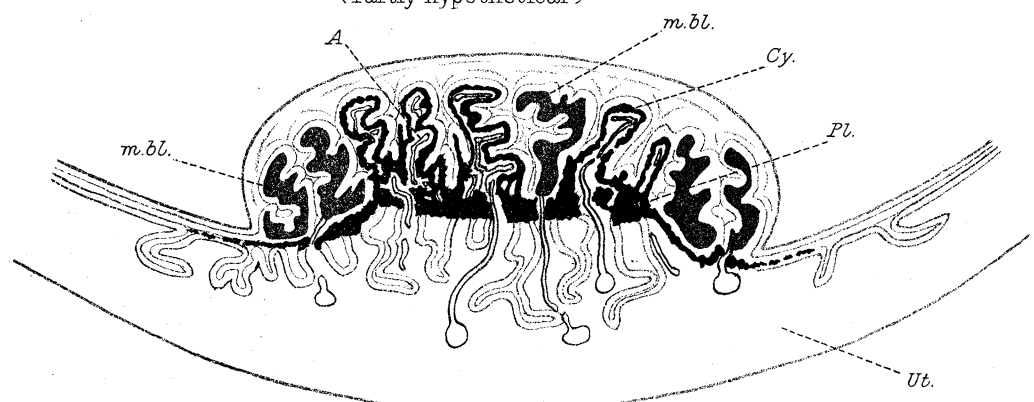


SUS
(Equus, Cetacea? Sirenia? Edentata?)
(Prosimia??)

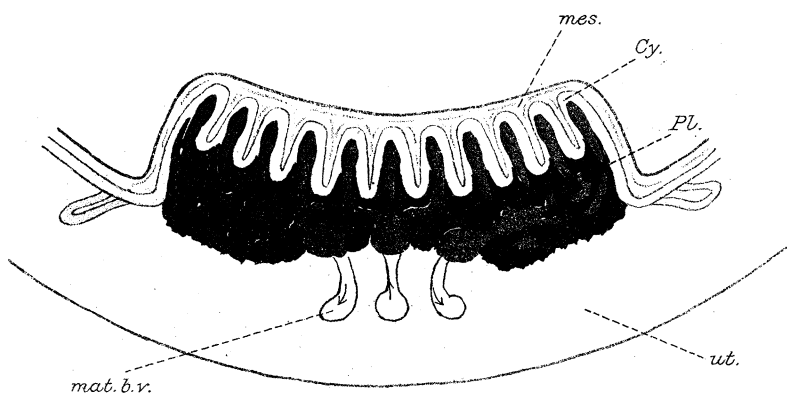
OVIS.



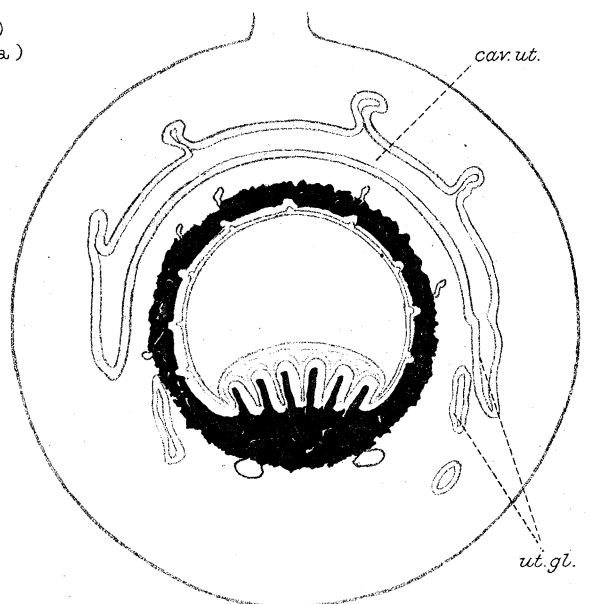
ELEPHAS.
(Partly hypothetical)



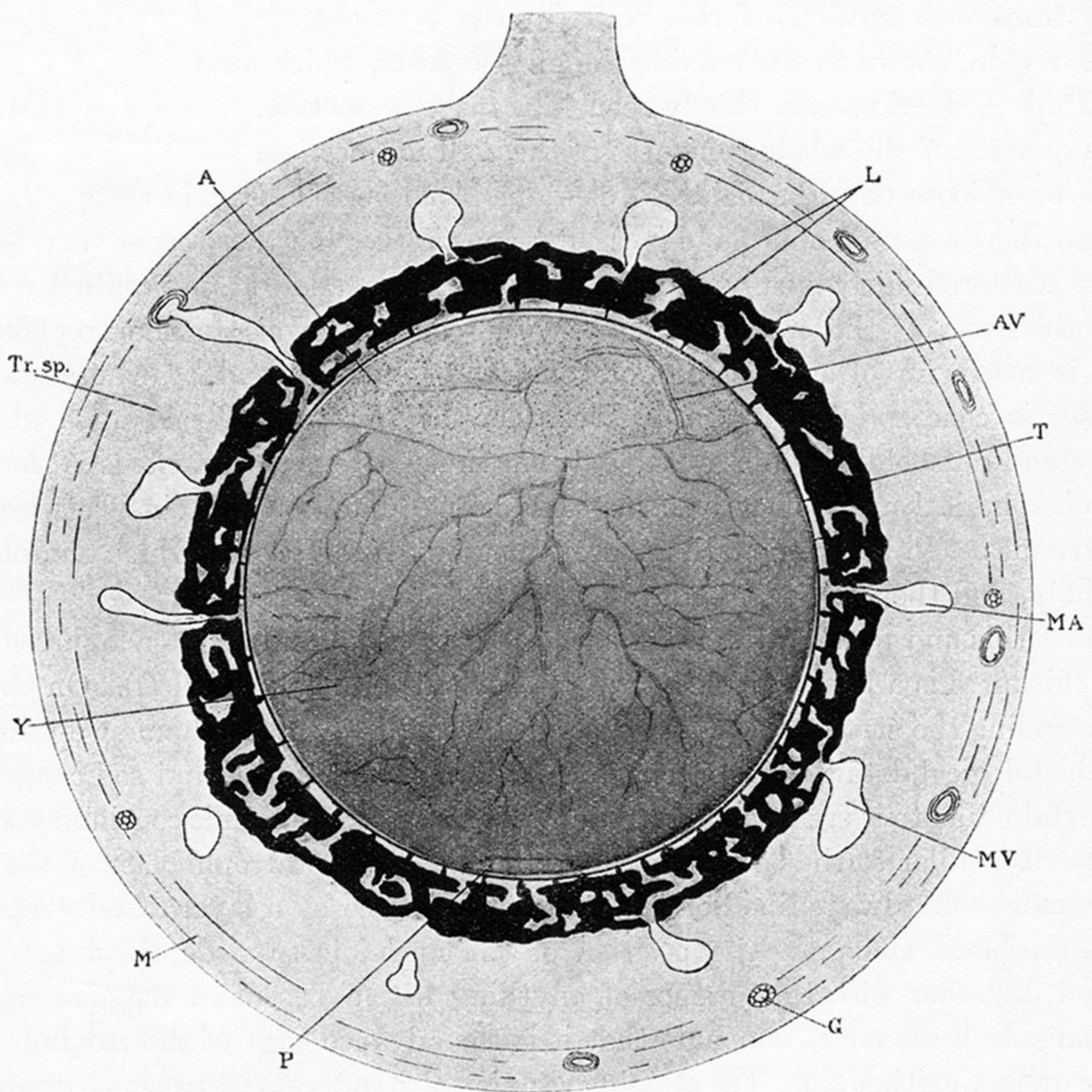
CANIS.
(Duvai)
(Carnivora, Pinnipedia?)
(Proxime access. Chiroptera)



ACOMYS.
Typical of most rodents.

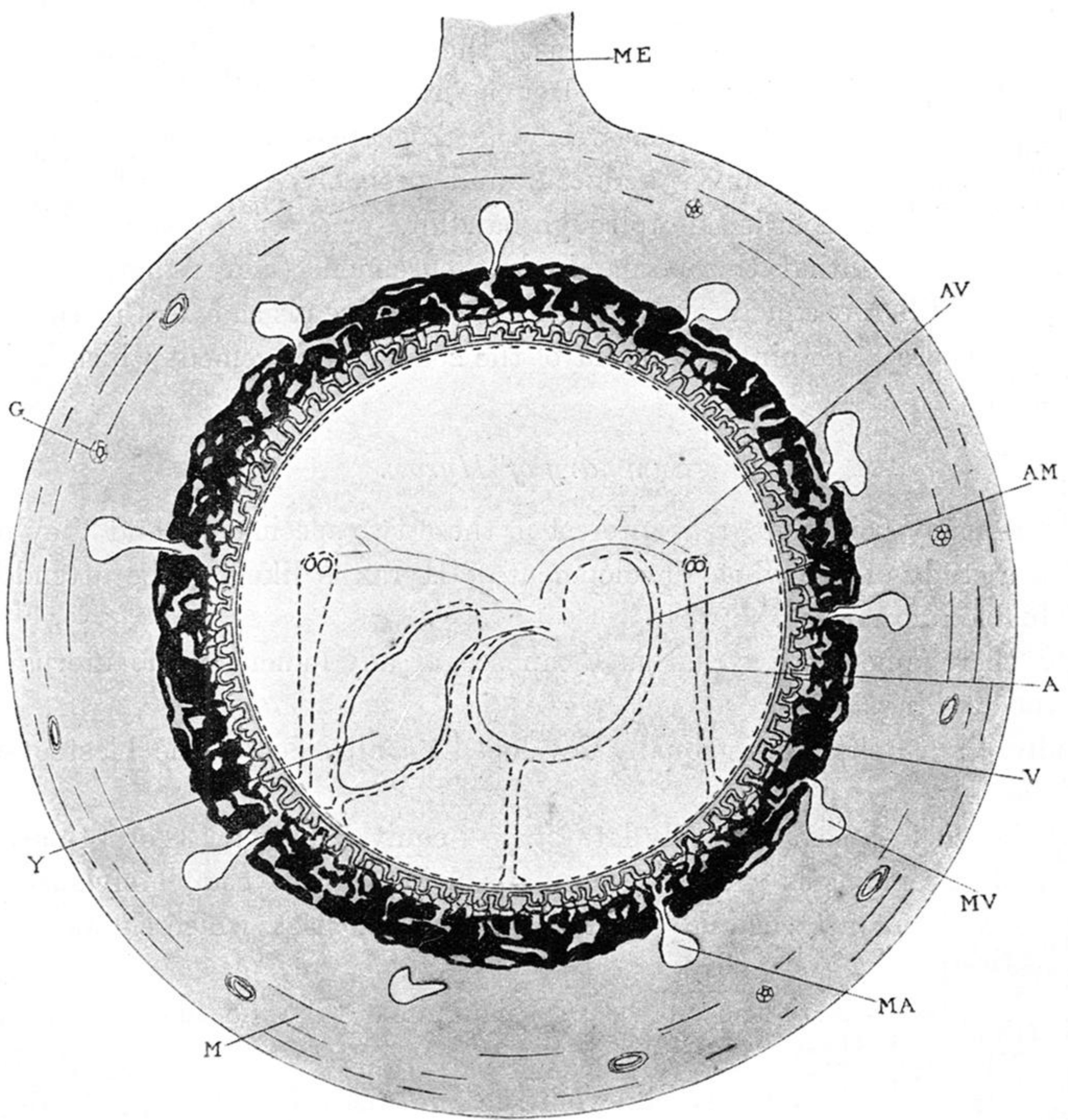


ERINACEUS
(Hyrax)(Homo)
West, Newman chromo.



Text-fig. 11.—*Procavia* (Hyrax) *Capensis*. Wall of uterus and trophoblast of embryo seen in transverse section, the rest of the blastocyst bounded by the somatopleur in surface view. The dotted area of the latter is the allantois.

A, allantois; AV, allantoic blood vessel; G, uterine gland; M, muscle layer; L, lacunæ in trophoblast filled with extravasated maternal blood; MA, maternal artery; MV, maternal vein; P, lower pole of yolk sac; T, trophoblast; Tr. sp., trophospongial layer; Y, yolk sac.



Text-fig. 12.—Transverse section through the uterus and foetus of Hyrax.

A, lining layer of allantois (hypoblast); AM, amnion; AV, allantoic blood vessels; G, uterine gland; M, muscle layer; MA, maternal artery; MV, maternal vein; ME, mesometrium; V, mesoblast of villus of allantois; Y, yolk sac, greatly reduced in size.

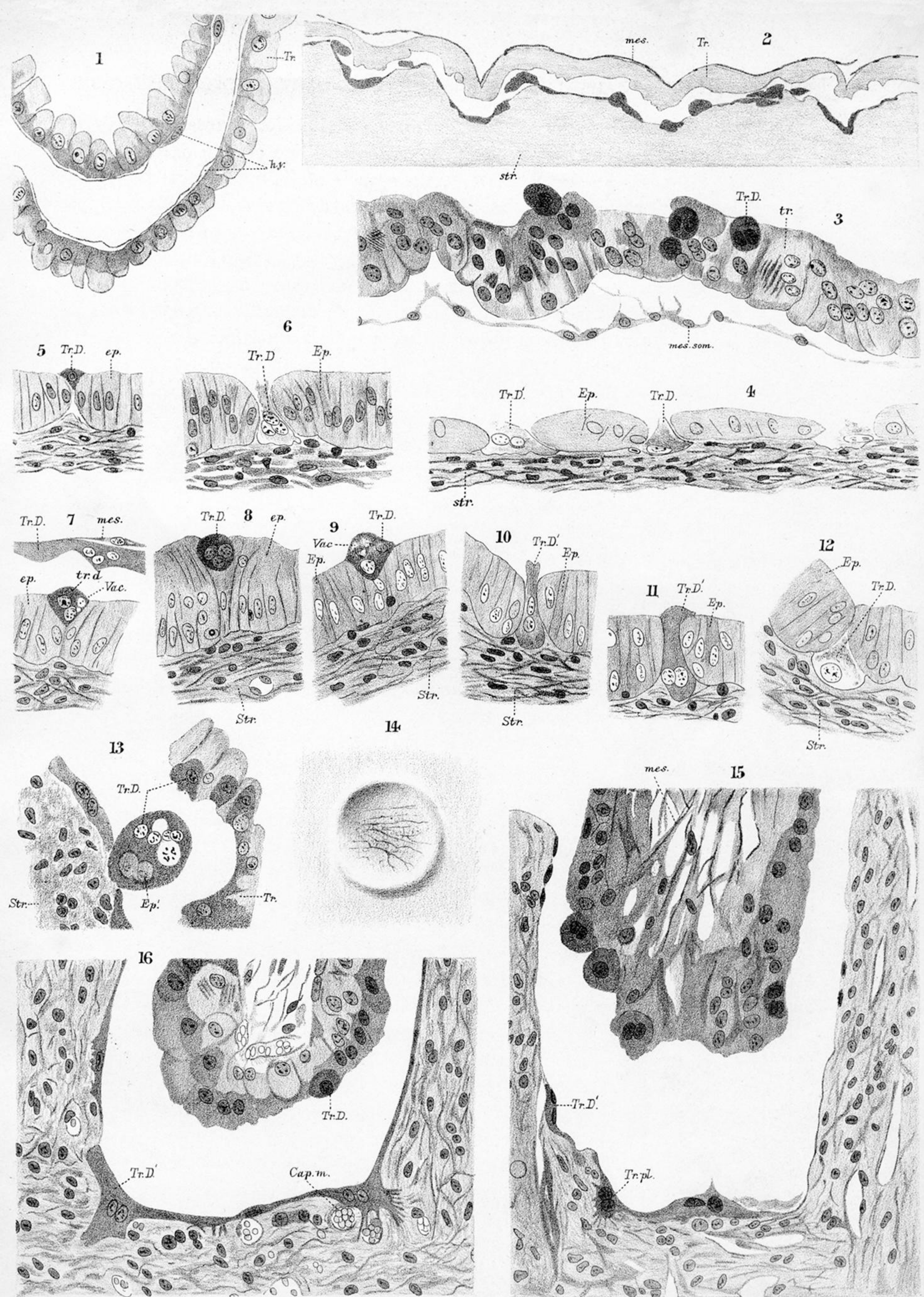


PLATE 9.

- Fig. 1. (Ovis 15.) Age 14 days. Section of part of the blastocyst, showing trophoblast and hypoblast. $\times 400$.
- Fig. 2. (Ovis 66.) Age 20 days. Transverse section through both uterine part and embryonic part of a cotyledon, showing the folds in the trophoblast and the sulci in the cotyledon in which the folds fit. The dark line indicates the very much broken uterine epithelium, together with the diplocaryocytes. $\times 97$.
- Fig. 3. (Ovis 67.) Age 19 days. Section through the thickened area of the trophoblast taken parallel to the ridges. The section shows that the trophoblast consists of two or three cells in thickness, and four more deeply staining cells, spherical in shape, three of which show two nuclei. Although the general trophoblast appears to be made up of several cells in thickness, yet many of the cells pass through the whole. $\times 400$.
- Fig. 4. (Ovis 67.) Age 19 days. Transverse section, showing the degenerating epithelium of a cotyledonary burr. The epithelium is seen to be separated by several trophoblast cells, which are probably derived from the trophoblast. $\times 400$.
- Fig. 5. (Ovis 67.) Age 19 days. A piece of epithelium from the cotyledonary burr of the uterus, showing a trophoblast cell (*Tr. D.*) $\times 400$.
- Fig. 6. (Ovis 67.) Age 19 days. A piece of the epithelium of the cotyledonary burr of the uterus. Trophoblast cell has now reached the base of the epithelium, and tends to separate the epithelium from the sub-lying stroma. $\times 400$.
- Fig. 7. (Ovis 66.) Age 20 days. A piece of the epithelium of the cotyledonary burr and of the trophoblast, a diplocaryocyte is seen to have just left the trophoblast layer, and to be forcing its way as a wedge between the uterine epithelial cells. It is very much deeper in colour than any other tissue. It shows the two nuclei, and a very distinct vacuole which is characteristic of these cells at this period. $\times 400$.
- Fig. 8. (Ovis 66.) Age 20 days. A piece of the epithelium of the uterus from the side of a cotyledonary burr, showing one of the trophoblast cells just entering the epithelium. It is much darker in colour than the epithelial cells, and contains three nuclei. $\times 400$.
- Fig. 9. (Ovis 66.) Age 20 days. Another piece of the epithelium from the side of a cotyledonary burr, showing an invading trophoblast cell. $\times 400$.
- Fig. 10. (Ovis 66.) Age 20 days. A piece of the epithelium of a cotyledonary burr, showing the complete penetration of the epithelium by a trophoblast cell (diplocaryocyte). $\times 400$.
- Fig. 11. (Ovis 66.) Age 20 days. Another portion of the epithelium of a cotyledonary burr, showing the arrival of the diplocaryocyte at the base of the epithelium. $\times 400$.
- Fig. 12. (Ovis 66.) Age 20 days. Another portion of the epithelium from the side of a cotyledonary burr, showing trophoblast cell beneath the epithelium. Its cytoplasm is very vesicular. $\times 400$.
- Fig. 13. (Ovis 66.) Age 20 days. Another portion through the blastocyst and uterine tissue near the centre of a cotyledon showing the process of destruction of the uterine epithelium. In the round mass (*Tr. D.*) I take the clearly marked nuclei to be of trophoblastic origin, and those (*Ep.*) which are obviously in an advanced stage of degeneration to be uterine epithelial cells undergoing destruction. $\times 400$.
- Fig. 14. (Ovis 66.) Age 20 days. Surface view of a cotyledonary burr, showing the sulci formed by the ridges already present on the blastocyst. $\times 5$.
- Fig. 15. (Ovis 69.) Age 31 days. A section taken through the distal end of a foetal villus and the uterine crypt. The foetal villus shows a core of loose mesoblastic tissue covered by a layer of ordinary trophoblast cells, and here and there a diplocaryocyte, the nuclei of which stain very deeply. The crypt is lined here and there by some darkly staining cells with darkly staining nuclei. These are to be regarded as having been derived from the trophoblast (diplocaryocytes). Certain of these near the base (*Tr. pl.*) show a connection between the cytoplasm and the strands of protoplasm of the stroma. The space between the villus and the crypt is an artifact due to great contraction of the mesoblastic core of the villus which, in the natural state, is gelatinous.
- Fig. 16. (Ovis 68.) Age 35 days. A section taken longitudinally through one of the crypts and the apex of a villus. The crypt is completely lined by a layer of trophoblast cells, some of which are in protoplasmic connection with the stroma cells. The double nucleate condition is seen at the two corners. Diplocaryocytes, also on the point of budding off, are seen on the villus. The trophoblastic cells are in close contact with the capillaries of the stroma. $\times 400$.

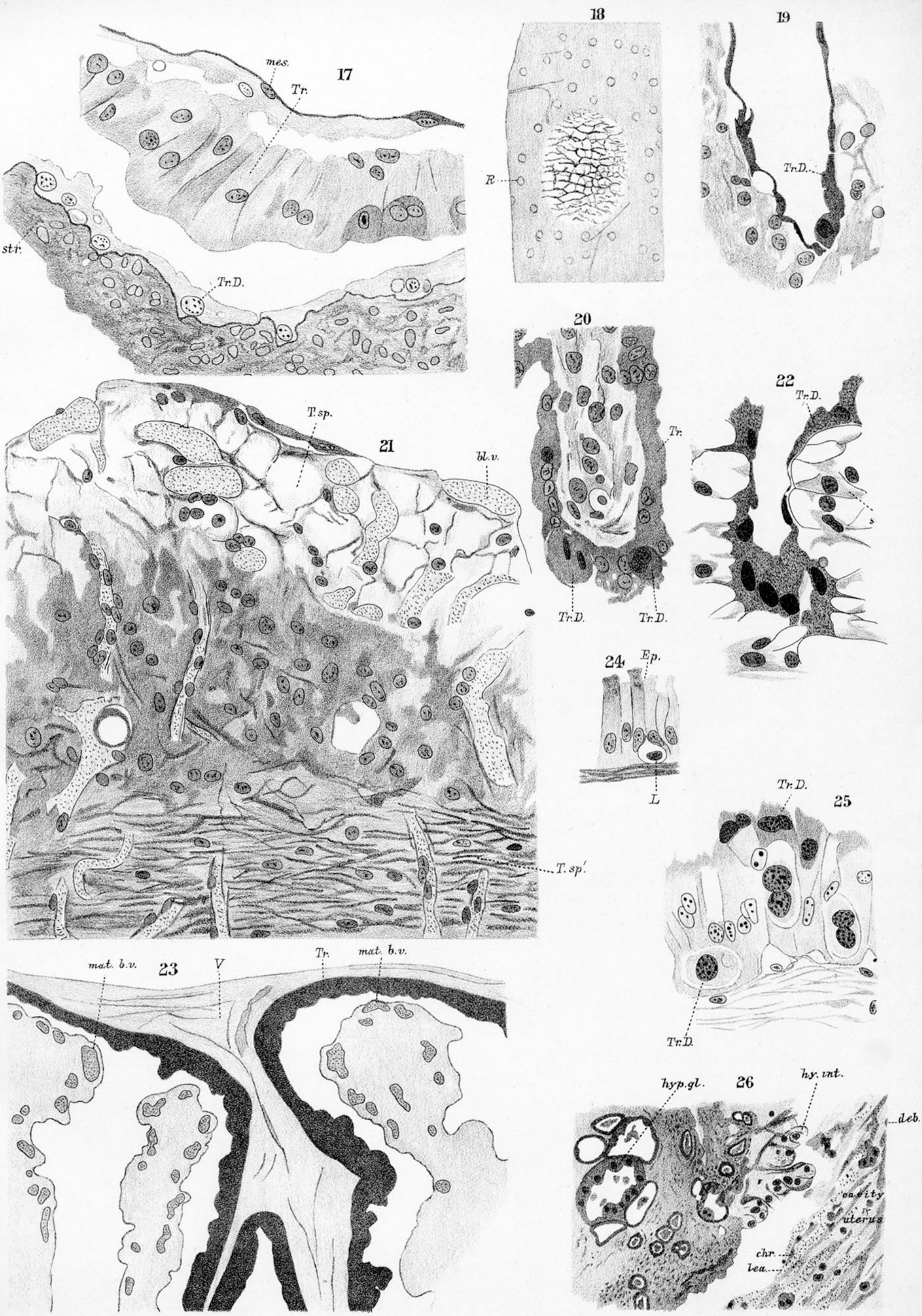


PLATE 10.

- Fig. 17. (Ovis 66.) Age 20 days. Stained with borax carmine and picronigrosin. Section through the wall of the blastocyst and uterine tissue of a cotyledon; the uterine epithelium has been entirely absorbed; the few brightly staining nuclei lying in loose vesicular cytoplasm are the diplocaryocytes, which now form an irregular plasmodial layer over the stroma. $\times 400$.
- Fig. 18. (Ovis 11.) Age 49 days. One of the patches of the villi on the chorion in the region of the embryo; the ridges and furrows running transversely are very conspicuous. $\times 10$.
- Fig. 19. (Ovis 11.) Age 49 days. Section taken longitudinally through the apex of a foetal villus. Various stages in the formation and separation of the diplocaryocytes can be seen. $\times 400$.
- Fig. 20. (Ovis 11.) Age 49 days. A section taken longitudinally through the base of a crypt. A doubly nucleated cell appears, clearly forming part of the protoplasmic lining of the crypt. $\times 400$.
- Fig. 21. (Ovis 47.) Age 26 days? A piece of the cotyledonary burr showing the development of the blood vessels and lymphatic spaces close to the surface. Little pieces of the trophoblast are seen in places. The lower part of the figure shows the original stratified condition of the stroma through which the capillaries run perpendicular to the general surface. It is above this area, that is to say in the more superficial part of the cotyledon, that the blood vessels and lymphatics are developing. $\times 400$.
- Fig. 22. (Ovis 11.) Age 49 days. Transverse section through the fundus of the crypt at an early stage; the stroma cells are very much vacuolated, the trophoblast cells of the embryo line the fundus of the crypt and tend to work their way in between the cells and the stroma. $\times 450$.
- Fig. 23. (Ovis 45.) Age 44 days. A section passing through the base of one of the foetal villi, showing the expanded outer end of the intercrypt columns of the cotyledon. The surface of these terminations of the columns are traversed by wide blood vessels. The destruction of these blood vessels probably leads to the extravasation of blood at a later period. $\times 97$.
- Fig. 24. (Ovis 65.) Age full term. A piece of the epithelium of the gland showing leucocyte at the base of the epithelium. $\times 450$.
- Fig. 25. (Ovis 65.) Age full term. Stain thionin, eosin and orange. A portion of the trophoblast at the base of a villus, where it is bathed in maternal extravasated blood, which shows the character of the diplocaryocytes and the way in which they take their origin at the base of the trophoblast and work their way outwards. As they reach the surface the nuclei become contracted and degenerate. $\times 500$?
- Fig. 26. (Ovis 65.) Age full term. A section taken through a piece of the wall of the upper part of one of the horns of the uterus. Both the glandular epithelium and the interglandular tissue are undergoing a process of hypertrophy followed by desquamation. All the sections of glands show *débris* within their lumina. Large numbers of leucocytes, *débris* of cells and grains of chromatin, fill the cavity of the uterus. $\times 200$.

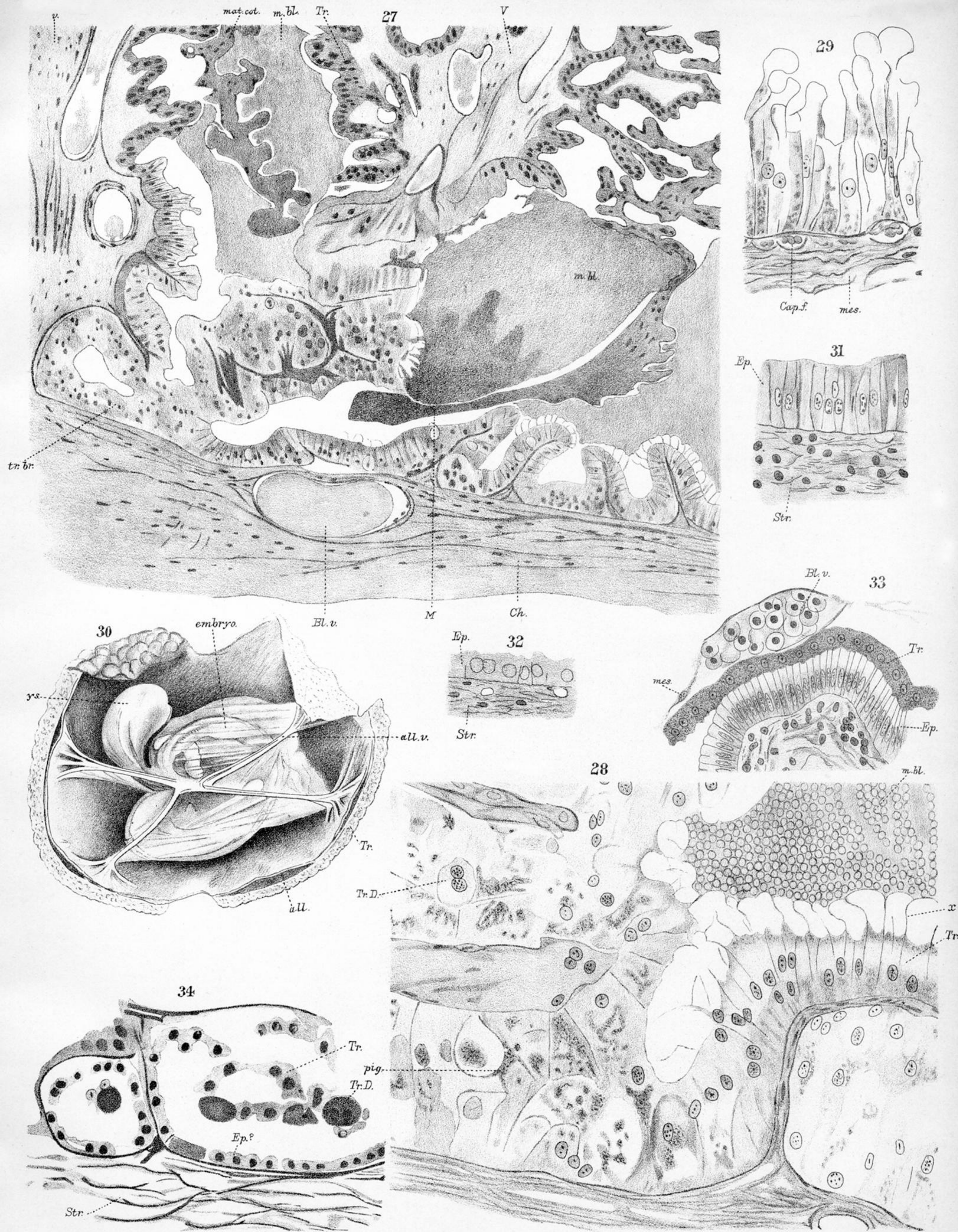


PLATE 11.

Fig. 27. (Ovis 65.) Age full term. Section taken vertically through the foetal side of a cotyledon. The lower part of the section shows the chorion with blood vessels. The trophoblast is thrown into folds and on the left side is continued over a villus which contains blood vessels. Large lacunæ of extravasated maternal blood bathe the folds of the trophoblast and the bases of the villi. The maternal tissue stains a more orange tint than the foetal tissues and the nuclei are smaller and flattened. There is very little trophoblast lining the maternal tissues in this region. The large irregular piece of maternal tissue which lies between the folds of the trophoblast shows no sign of a covering of trophoblast and is almost quite devoid of nuclei. $\times 400$.

Fig. 28. (Ovis 65.) Age full term. A small portion of a region corresponding with that of the above section, under a higher power. This shows the tendency to a breaking up of the trophoblast where the folds lie in contact with each other. Large pigment granules are scattered in little masses throughout the folds. At one corner the section passes through one of the lacunæ of extravasated blood. Where the trophoblast cells are in contact with this blood there is no sign of breaking up, each cell is clearly defined, with nucleus, and with a sac-like termination which stretches out into the blood lacuna. $\times 400$.

Fig. 29. (Ovis 65.) Age full term. A transverse section of a small piece of the chorion epithelium showing the capillaries of the chorion lying close against the epithelium, and the sac-like terminations of the epithelial cells. $\times 900$.

Fig. 30. (Hyrax.) (*Procavia capensis*.) A figure of the blastosphere of Hyrax removed from the walls of the uterus and laid open. The thick outer layer is the trophoblast, within which the allantois is seen to be closely lining the trophoblast. From the allantois to the embryo four main vascular trunks converge and, together with the yolk sac which lies to the left of the embryo, disappear into the embryo. $\times 5$.

Fig. 31. (Sus 31.) Age $4\frac{1}{2}$ days. A portion of the epithelium and stroma of the uterus of the pig. $\times 400$.

Fig. 32. (Sus 15.) Age 16 days. A portion of the epithelium and stroma of the uterus of the pig at a later date showing a degeneration in the epithelium. $\times 400$.

Fig. 33. (Sus 7.) Age 20 days. A section taken through the wall of the uterus and the wall of the blastocyst. Below is the stroma of the uterus lined by a regenerated epithelium consisting of long thin columnar cells with convex outer surfaces. Closely lining this is the trophoblast of the blastocyst, which is a syncytium, and fits closely in between the tops of the uterine epithelial cells. A blood vessel is cut across and shows the large nucleated foetal corpuscles. $\times 400$.

Fig. 34. (Bos 1.) Age uncertain. A section taken through a fundus of crypt of one of the cotyledons showing a portion of the villus within it. The cells lining the crypt are epithelial in appearance, and show no sign of forming a syncytium or of connection with the adjoining stroma cells. In the villus are seen two kinds of trophoblast cells, ordinary cubical cells and large deeply staining doubly nucleated cells (diplocaryocytes). $\times 400$.

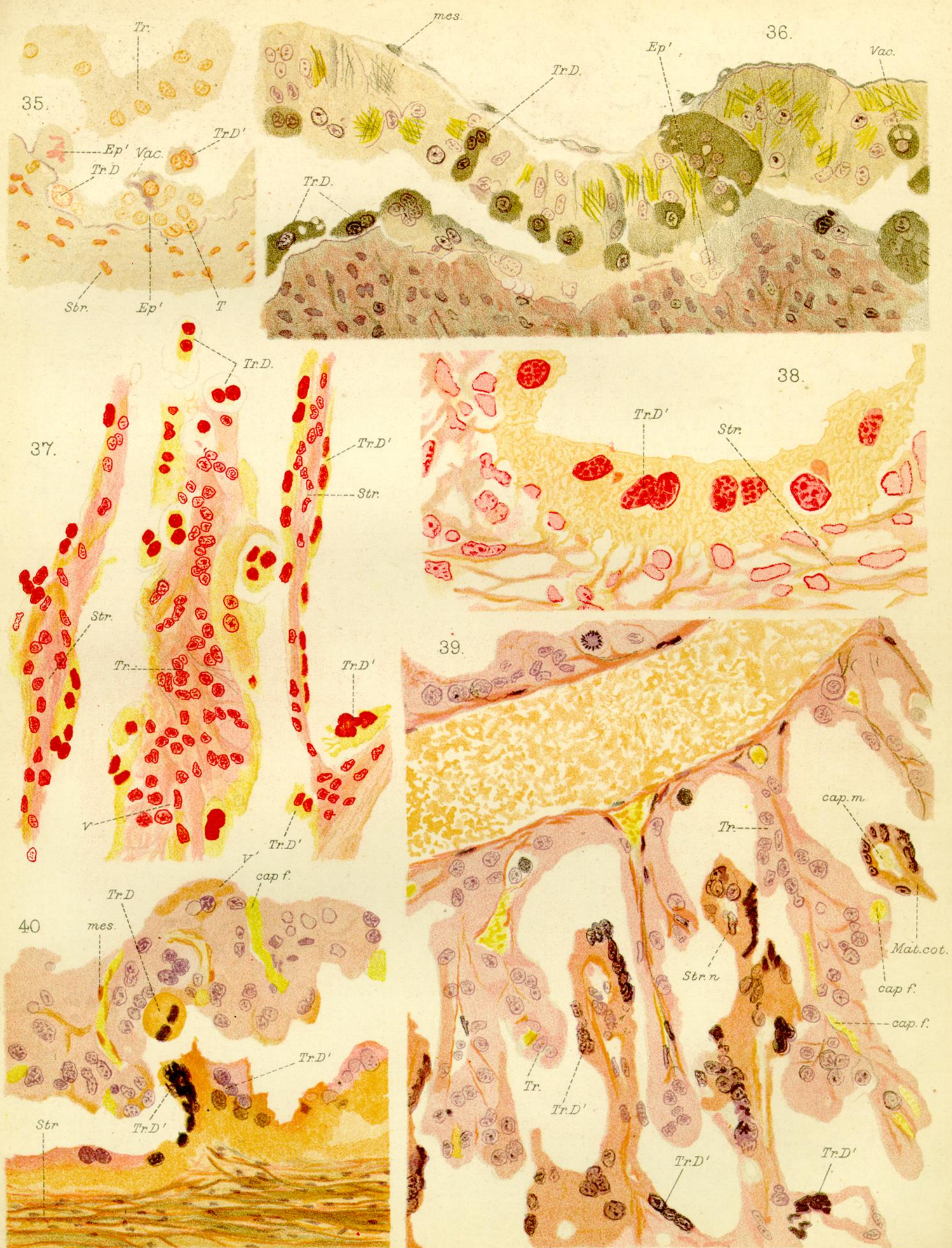

PLATE 12.

Fig. 35. (Ovis 66.) Age 20 days. Stained with borax, carmine, and picro nigrosin. Section through the wall of the blastocyst and uterine tissue of a cotyledon showing destruction of the uterine epithelium. The brightly stained nuclei (*Tr. D.*) are the nuclei of those cells which have migrated from the trophoblast, forced their way between the epithelial cells, and are now lining the uterine stroma. The masses (*Ep.*) are the remains of uterine epithelium rapidly undergoing disintegration. The dark staining cell with bright nucleus and a vacuole is one of the diplocaryocytes just attacking that piece of epithelium. $\times 400$.

Fig. 36. (Ovis 66.) Age 20 days. Stained with hæmalum, thionin, orange G. A section taken near the centre of a cotyledon, showing very clearly the conspicuous character of the diplocaryocytes. Most of the ordinary trophoblast cells, which have nuclei which show very little chromatin, have their cytoplasm filled with long bodies stained yellow, probably of proteid nature. $\times 400$.

Fig. 37. (Ovis 12.) Age 52 days. A section taken longitudinally through the middle of the cotyledonary area. The stroma cells are darker in colour and are lined by a very irregular layer of trophoblast cells. In the middle is a section through one of the villi taken close to the surface so that only the epithelium is cut through. The diplocaryocytes are recognised by the more deeply staining quality of their nuclei, and by the fact that the protoplasm is drawn away from the general surrounding tissue. $\times 400$.

Fig. 38. (Ovis 12.) Age 52 days. A highly magnified section through the base of one of the crypts showing the plasmodium formed by the trophoblast cells; the strands, processes of protoplasm, are seen to be in direct connection with the cells of the stroma. $\times 900$.

Fig. 39. (Ovis 65.) Age full term. A section taken vertically through the inner part of a cotyledonary area showing the interlocking of the foetal and maternal tissues. The foetal tissue shows a large blood vessel which occupies nearly the whole of the villus. From it small capillaries run out at right angles, and are covered by a layer of trophoblast. These fit into little crypts, which are lined by the trophoblast syncytium, the cells of which stain more deeply. Many of the nuclei are shrivelled and in a state of degeneration. $\times 400$.

Fig. 40. (Ovis 65.) Age full term. Section through the base of a crypt and apex of a villus. The foetal blood vessels are seen to run close to the surface of the villus, the crypt is lined by a thick plasmodial layer derived from the diplocaryocytes of the embryo. One diplocaryocyte is seen on the point of detachment from the villus to join the plasmodium. $\times 400$.

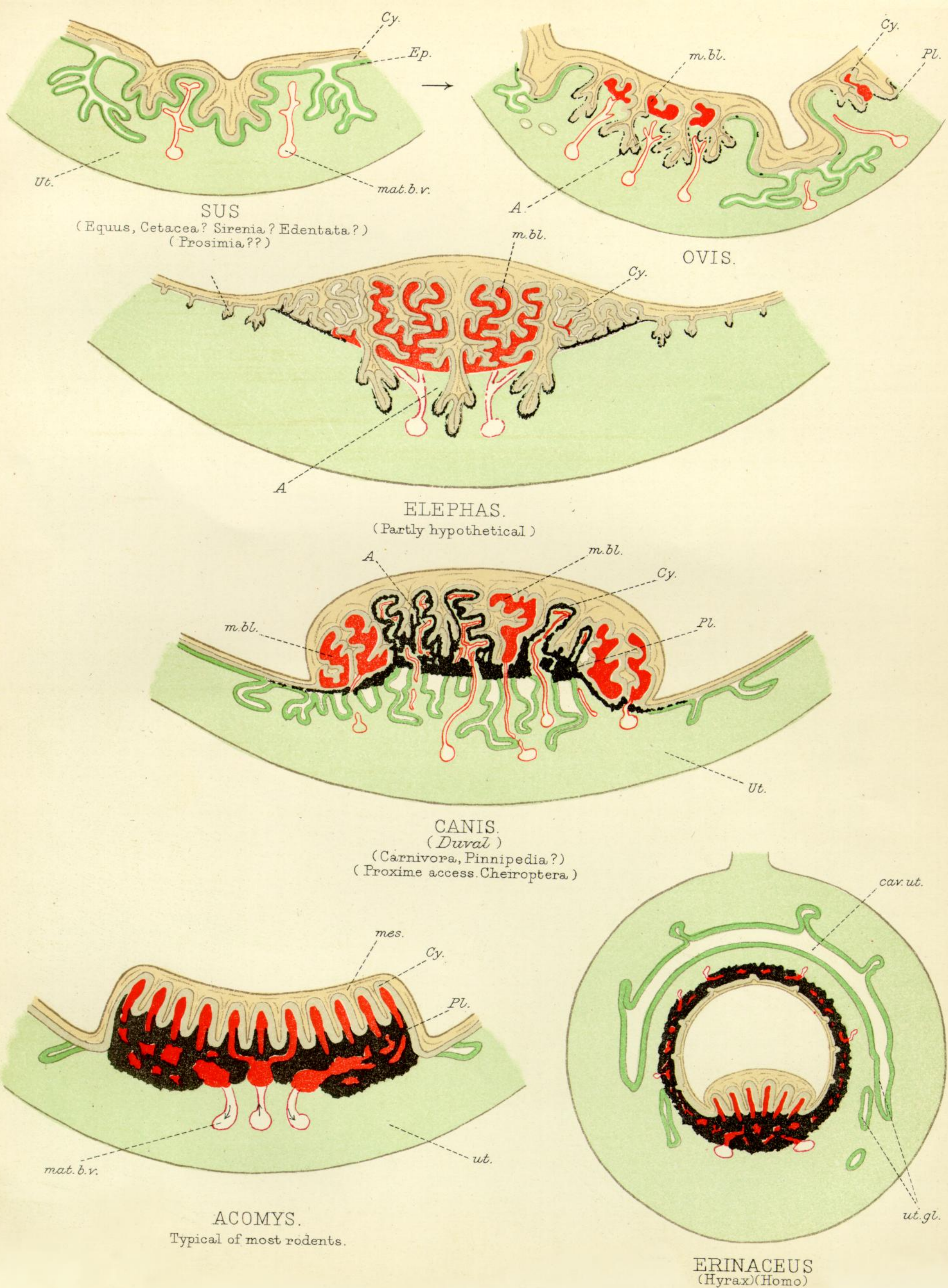


PLATE 13.

Diagrams to illustrate the relations of the placenta of the Ungulata Vera and Sub-Ungulata to that of the cumulate type, as exemplified by Acomys and Erinaceus.

Maternal tissues are in green, except maternal blood, which is vermilion. A white space bordered by vermilion is maternal blood vessel; masses of vermilion are lacunæ of extravasated maternal blood. Plasmodiblast is black, cytoblast is blue, foetal mesoblastic tissues stone colour.

Fig. 1. (*Sus*.) Plicate. There is no permanent destruction of uterine epithelium. There is no extravasated maternal blood. The uterine glands pour secretion on to special circular areas of the chorion.

Fig. 2. (*Ovis*.) The placenta is clearly on the same plan as above; but at certain points a slight thickening occurs of the trophoblast, at which spots the uterine epithelium is destroyed. There are small lacunæ of extravasated maternal blood. Plicate.

Fig. 3. (*Elephas*.) Half-term placenta. It differs little in essential features from Ovis. The most important is the great development of the extravasated blood lacunæ between the folds of the subzonal membrane (or of chorion), which, no doubt, result in a well-established circulation. At the borders the mode of development of the system is shown where the blood is seen to be penetrating between the closely-packed foetal folds. The condition of glands is not known. Plicate.

Fig. 4. (*Canis*.) The lacunæ are more evident than in Ovis, but probably do not form part of the regular circulatory system. By a greater accumulation of plasmoditrophoblast, a nearer approach to the cumulate type is attained.

Fig. 5 (*Acomys*) and Fig. 6 (*Erinaceus*) are cumulate. The trophoblast, greatly thickened, is honeycombed by lacunæ in which maternal extravasated blood circulates. The importance of the glandular secretion is greatly diminished.